CONGENITAL CARDIOLOGY TODAY

Timely News and Information for BC/BE Congenital/Structural Cardiologists and Surgeons

Volume 10 / Issue 9
September 2012
International Edition

IN THIS ISSUE

UPCOMING MEDICAL MEETINGS
See website for additional meetings

2012 Specialty Review in Pediatric Cardiology Board Review/ CME Course
Sep. 10-14, 2012; Chicago, IL USA
www2.aap.org/sections/cardiology/pediatric_cardiology/2012/

Southeastern Pediatric Cardiovascular Society (SEPCS) Conference 2012
Sep. 13-15, 2012; Atlanta, GA USA
www.sepcs.org

8th Advanced Symposium on Congenital Heart Disease in the Adult, Royal College of Surgeons
Sep. 24-15, 2012; London, UK
www.achd8.co.uk

Univentricular Heart Symposium
Sep. 25-27, 2012; Saudi Arabia
www.pscc-conferences.com

CONGENITAL CARDIOLOGY TODAY
Editorial and Subscription Offices
16 Cove Rd, Ste. 200
Westerly, RI 02891 USA
www.CongenitalCardiologyToday.com

Wolff-Parkinson-White (WPW) Syndrome Causing Cardiogenic Shock and Multi-Organ Failure in Greenlandic Newborn

By Karen Bjorn-Mortensen, MD; Inga Hjuler, MD; Nikolaj Ihlemann, MD

Key words: arrhythmia, tachycardia, heart failure, multiorgan system failure, acute metabolic derangement

Abbreviations: None

Financial disclosure: The authors have no financial relationships relevant to this article to disclose.

Conflict of Interest declarations: The authors have no conflicts of interest relevant to this article to disclose.

A 5-week old infant, born 4 weeks before term and previously healthy, was admitted to Dronning Ingrid's Hospital with respiratory distress, supraventricular tachyarrhythmia, severe metabolic acidosis, intestinal bleeding and abnormal kidney and liver function.

The boy was reported as a previously healthy baby boy until two days prior to hospitalization. The parents contacted the local nursing station in an isolated village outside one of Greenland's northernmost cities due to, what the parents described as sudden coldness of the infant's extremities and cheeks. The baby had been crying during the night for 2 days, but had been well during the day. Feces had turned green, but otherwise, the boy had showed normal responses in respect to eating, drinking and urine output.

At the local nursing station, the boy was diagnosed as having pneumonia due to laxity, cyanosis and tachypnea. An oral antibiotic was started, since nobody present was qualified to gain intravenous access.

Before arriving in Nuuk, the capital of Greenland, another 24 hours was spent at a local hospital in Northern Greenland where doctors made the diagnose of pneumonia and continued antibiotic treatment with intramuscular injection of ampicillin. The reports were of a critically-ill infant, who needed to be evacuated as soon as possible. Due to the local weather conditions, the boy and his mother did not reach Nuuk until a 4 days after onset of symptoms.

At the time of admittance to Dronning Ingrid's Hospital, the boy had tachypnoea of 100 breaths per minute and tachycardia with a heart rate of 280, but peripheral saturation and capillary responses were normal. Venous gases showed a metabolic acidosis with respiratory compensation, with Base excess -14 mmol/l, pH 7.34, pCO_2 29 kPa and pO_2 69. No significant leucocytosis and only a small rise in C-reactive

Medtronic

A perfect melody of compassionate hearts, innovative minds and skilled hands.

Melody®

TRANSCATHETER PULMONARY VALVE (TPV) THERAPY

Worldwide, over 3,000 congenital heart disease patients have benefited from Melody TPV therapy. We remain committed to providing innovative options for your clinical management of these patients over their lifetime.

Visit www.Melody-TPV.com
and restore hope for your patients.

Melody® Transcatheter Pulmonary Valve
Ensemble® Transcatheter Valve Delivery System

Indications

The Melody® Transcatheter Pulmonary Valve is indicated for use in patients with the following clinical conditions:

- Patients with regurgitant prosthetic Right Ventricular Outflow Tract (RVOT) conduits with a clinical indication for invasive or surgical intervention, OR
- Patients with stenotic prosthetic RVOT conduits where the risk of worsening regurgitation is a relative contraindication to balloon dilatation or stenting.
- Existence of a full (circumferential) RVOT conduit that was equal to or greater than 16 mm in diameter when originally implanted.
- The intended lifetime for the Melody® device is 2 years.

Contraindications

- Venous anatomy unable to accommodate a 22 Fr size introducer sheath; Implantation in left heart;
- Unfavorable right ventricular outflow tract for good stent anchorage;
- Severe right ventricular outflow obstruction, which cannot be dilated by balloon;
- Obstruction of the central veins;
- Clinical or biological signs of infection;
- Active endocarditis;
- Known allergy to aspirin or heparin;
- Pregnancy.

Potential Complications / Adverse Events: Potential procedural complications that may result from implantation of the Melody device include the following: rupture of the RVOT conduit, compression of a coronary artery, perforation of a major blood vessel, embolization or migration of the device, perforation of a heart chamber, arrhythmias, allergic reaction to contrast media, cerebrovascular events (TIA, CVA), infection/sepsis, fever, hematoma, radiation-induced erythema, pain at the catheterization site.

Potential device-related adverse events that may occur following device implantation include the following: stent fracture resulting in recurrent obstruction, endocarditis, embolization or migration of the device, valvular dysfunction (stenosis or regurgitation), paravalvular leak, valvular thrombosis, pulmonary thromboembolism, hemolysis.

For additional information, please refer to the Instructions For Use provided with the product.

The Melody® Transcatheter Pulmonary Valve and Ensemble® Transcatheter Delivery System has received CE Mark approval and is available for distribution in Europe. Additionally, a Medical Device Licence has been granted and the system is available for distribution in Canada.

Melody and Ensemble are trademarks of Medtronic, Inc.

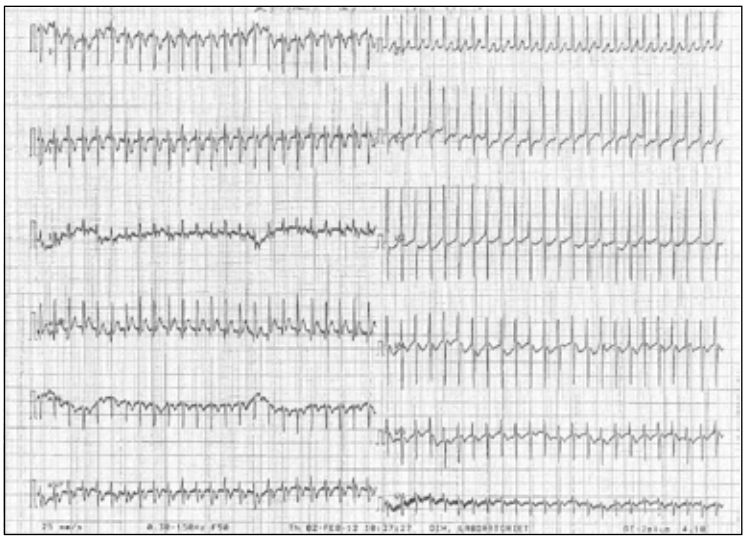

Figure 1: Initial ECG, showing a fast regular tachyarrhythmia with narrow complexes.

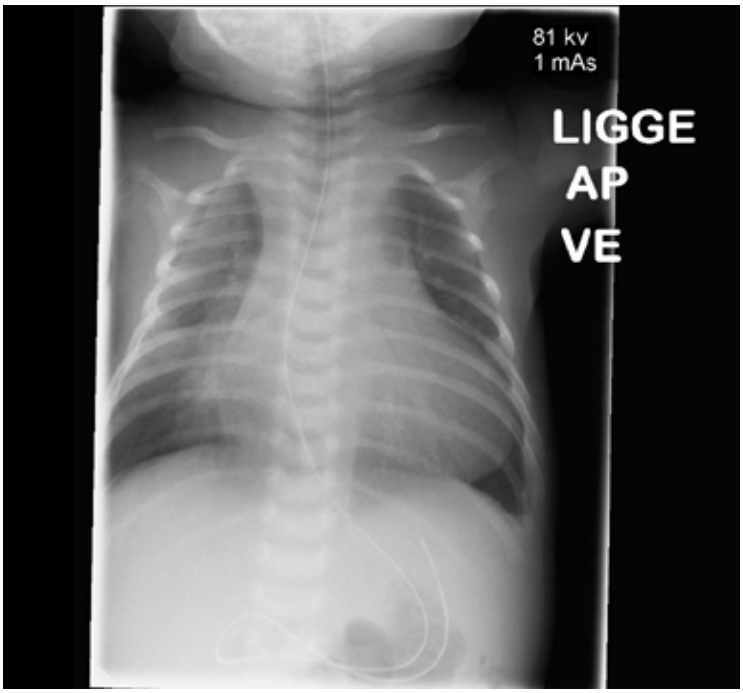

Figure 2: Initial chest x-ray. The heart shadow shows a dilated heart.

protein were present. Blood sugar was very low 0.6 mmol/L.

An ECG showed a regular tachyarrhythmia with narrow complexes (see Figure 1); chest x-ray and echocardiography (see Figure 2) showed a massively dilated heart with decreased contractility, but no structural abnormalities.

Figure 3: Echocardiography on the morning after conversion to sinus rhythm. Parasternal view showing a dilated left ventricle, left ventricle internal diameter of 24 mm.

On the suspicion of a septic state with cardiogenic impact, intravenous ceftriaxon and fluids were started immediately after arrival. To ease the infants breathing he was treated with C-PAP and the hypoglycemia with 10% glucose.

In an attempt to convert the supraventricular tachycardia, intravenous adenosine was given in a dose of first 150 µg/kg; later, then a dose of 300 µg/kg repeated two times was administered with no effect. Hereafter, a loading dose of digoxin was supplied with no immediate effect, and two more doses were planned. After a while the heart rhythm briefly changed to ventricular tachycardia, and then finally changed to sinus rhythm, with a heart rate of 185. A new echocardiography showed some improvement in the contractility, but the heart was still dilated.

Despite conversion to sinus tachycardia the infant's condition worsened during the next hour. Black, sweetly smelling feces were noted, the bowels turned silent, the stomach bloated and blood appeared in the nasogastric probe. Intravenous pantoprazole was given and blood transfusions prepared. Suddenly the boy turned grey, had apnea and desaturations, and was quickly intubated. New gases showed severe acidosis with pH 7,00, Base excess -21.[4,9] Blood samples showed a high creatinine and carbamide, and since the boy had not been urinating since a catheter was placed in the bladder at arrival, acute kidney failure was suspected. Altogether the boy was diagnosed with a probable intraabdominal disaster causing severe septicemia resulting in multi-organ failure. Due to the severe lacidosis, kidney failure, liver failure, decreased contractility of the heart and apnea, treatment seemed difficult and hopes of the boy surviving were small.

Despite all odds the boy did not die. A couple of hours later he had turned pink, muscle tone, reflexes, respiration and pulse had normalized and the boy seemed hungry. Repeated venous gases, creatinine, carbamide and liver values gradually normalized. Diapers

were repeatedly wet, and feces turned to a normal color again. His stomach was soft and bowel sounds normal.

A new echocardiogram showed an almost normally contracting heart and an almost normal heart size (see Figure 3), with a further reduction in heart size on the second day after conversion (see Figure 4). Heart rate was normal.

Due to exhaustion he still needed C-PAP, but during the next 12 hours his condition continued to improve until his heart rate suddenly switched to a supraventricular tachyarrhythmia again. A higher dose of Adenosine was given which instantly converted his heart rate back to normal. ECG recorded, showed a characteristic delta wave (see Figure 5), and the diagnosis of Wolff-Parkinson-White Syndrome was made. Treatment with beta blocker was initiated to prevent further tachyarrhythmia.

Figure 4: Echocardiography two days after conversion to sinus rhythm. Parasternal view showing a normal ventricle, left ventricle internal diameter of 19 mm.

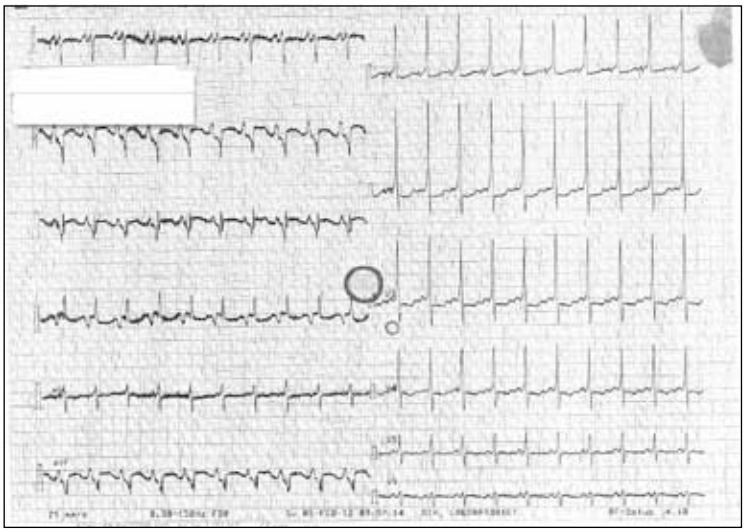

Figure 5. ECG after conversion with adenosine. Regular sinus rhythm with characteristic delta waves most prominent in V1-V3.

Discussion

Fetal and neonatal cardiac arrhythmias are not common, but well-known; the same is true for infants as well. We report this case not only because of the finding of Wolff-Parkinson-White Syndrome, but also because of the unusual presentation of the infant's condition. Due to local and geographical conditions the boy had been ill for four days before reaching our department. Most likely he survived four days with a WPW tachyarrhythmia without treatment. The incessant tachyarrhythmia caused a cardiogenic shock and multi-organ failure making it difficult to determine whether the case was a primary arrhythmia or arrhythmia due to septicemia. Rarely do doctors get to follow the symptoms and complications caused by an untreated cardiac arrhythmia in infants. Reduced left ventricular function,[1] palpitations, syncope, chest pain, heart failure and cardiogenic shock have all been reported associated with WPW,[2] but the presentation with cardiogenic shock and multi-organ failure is not common. Heart failure due to WPW is more often seen in infants at an older age[3] and only after prolonged period of untreated supraventricular tachycardia.[4]

The prognosis of WPW presenting before 1 year of age is usually good, with the disappearance of the syndrome in more than 80% of cases;[5] preventive treatment with beta blockers is possible without long-term side effects. Treatment with radio frequency catheter ablation is possible, [6] but should be postponed until the child weights approximately 15 kg, and is at least the age 12 months, especially as a high percentage of very young children show spontaneous resolution.

In this case long-term prognosis had been irrelevant, if the attempt to convert his supraventricular tachycardia had been unsuccessful. Even though we suspected a late state of septicemia, the infant was still treated with adenosine and digoxin, possibly leading to a change in heart rhythm. The importance of differential diagnosis in pediatric patients with severe metabolic acidosis and multi-organ failure is clear.

References

1. Cadrin-Tourigny J, Fournier A, Andelfinger G, Khairy P. Severe left ventricular dysfunction in infants with ventricular preexcitation. Heart Rhythm. 2008 Sep;5(9):1320–2.
2. Soongswang J, Bhuripanyo K, Raungratanaamporn O, Sriratanasathavorn C, Krittayaphong R, Nutakul T, et al.

"Fetal and neonatal cardiac arrhythmias are not common, but well-known; the same is true for infants as well. We report this case not only because of the finding of Wolff-Parkinson-White Syndrome, but also because of the unusual presentation of the infant's condition."

6th WORLD CONGRESS

Paediatric Cardiology & Cardiac Surgery

17 – 22 February 2013, Cape Town, South Africa

PROGRAMME TRACKS

- Surgery, anaesthesia and intensive care
- Catheter interventions from fetus to adult
- Health systems and heart disease
- Adults with congenital and acquired heart disease
- Cardiology and the imaging revolution

Congress Secretariat

Contact the congress secretariat or visit www.pccs2013.co.za

P.O Box 6761, Roggebaai, 8012, South Africa

Telephone: +27(0) 21 408 9796 Fax: +27(0) 21 408 9954

E-mail: info@pccs2013.co.za

Hosted by:

www.pccs2013.co.za

Radiofrequency catheter ablation in pediatrics: experience at Siriraj Hospital. J Med Assoc Thai. 2000 Nov;83(11):1340–7.
3. Campa MA, Vaksmann G, Fournier A, Minassian V, Fouron JC, Davignon A. [Characteristics of paroxysmal atrial tachycardia in infants according to the age of onset]. Arch. Fr. Pediatr. 1990 Jan; 47(1):17–21.
4. Schlechte EA, Boramanand N, Funk M. Supraventricular tachycardia in the pediatric primary care setting: Age-related presentation, diagnosis, and management. J Pediatr Health Care. 2008 Okt;22(5): 289–99.
5. Vignati G, Annoni G. Characterization of supraventricular tachycardia in infants: clinical and instrumental diagnosis. Curr. Pharm. Des. 2008;14(8):729–35.
6. Tanel RE, Walsh EP, Triedman JK, Epstein MR, Bergau DM, Saul JP. Five-year experience with radiofrequency catheter ablation: implications for management of arrhythmias in pediatric and young adult patients. J. Pediatr. 1997 Dec;131(6):878–87.

CCT

Biographical Sketch of Corresponding Author

Graduated from the University of Copenhagen, Denmark, in January 2010. Since then she has been working as a physician at Queen Ingrids Hospital in Nuuk, Greenland, her main focus being internal medicine, infectious diseases and pediatrics. Currently she is working with primary care and doing research on HIV and tuberculosis in Greenland.

Corresponding Author:

Karen Bjorn-Mortensen, MD
Dept. of Internal Medicine and Pediatrics
Queen Ingrid's Hospital
Dronning Ingridsvej
3900 Nuuk, Greenland
Tel: 00299 255182
kbm@peqqik.gl

Inga Hjuler, MD
Dept. of Internal Medicine and Pediatrics
Queen Ingrid's Hospital
Dronning Ingridsvej
3900 Nuuk, Greenland

Nikolaj Ihlemann, MD
Department of Cardiology
University Hospital of Copenhagen Rigshospitalet, Denmark

Review of PICS~AICS 2012 in Chicago

By Karim Dlab, MD

With its vibrant atmosphere and its rich culture, the Windy City again provided an excellent venue for the 16th annual *PICS~ AICS* which was held at the Marriott Chicago Downtown in April 2012. The meeting featured extensive sessions and a large series of live cases transmitted from various centers around the globe that showcased the best in current interventional therapies for structural heart disease in children and adults. Despite its earlier start this year, more than 750 attendees made it to the meeting coming from 50 different countries. With more than 40% of attendees coming from outside the US, *PICS~AICS* is clearly established as an international symposium in the field of structural heart disease interventions. This year the format of the meeting was modified with mornings being dedicated to continuous live case transmissions - the hallmark of the symposium- and the afternoons to multiple breakout sessions running in simultaneously. This resulted in a total of 21 live case transmissions and 13 discussion breakout sessions. A total of 112 faculty members gave more than 130 talks! This reflects the vast educational opportunity this meeting provides. The breakout sessions in the afternoon ensured full coverage of various topics in congenital and structural heart disease, and attendees were free to choose sessions consistent with his/her particular educational interests and goals. There were special breakout sessions for nurses and technologists and younger interventionalists as well as sessions focusing on interventional therapies in the developing world.

The meeting took place over a total of four days with the first day featuring industry-sponsored workshops. Three workshops were held sponsored by St. Jude Medical, Gore and Cook Medical. The St. Jude Medical workshop featured an overview of the Amplatzer devices with Dr. J. Miro focusing on the new devices coming to the market including the Amplatzer Duct Occluder II Additional Sizes (ADO II AS) and the membranous VSD device (MEVSD2). The Gore workshop featured the Helex Septal Occluder for closing ASDs with a presentation of the worldwide data and experience with this device by Dr. N. Wilson. The third workshop presented by Cook Medical focused on the diagnosis and management of pulmonary arteriovenous malformations from both the radiological and cardiac aspects. Two world-renowned interventionalists, Drs. R. White and J. Pollak provided an extensive review of the diagnostic approach and the latest embolization coil techniques for the treatment of standard and complex cases of PAVMs with an overview of Cook Medical's full line of devices to access, target and treat PAVMs.

After the workshops, the first day ended with oral abstract presentations by junior interventional faculty. This took place in three separate sessions and the best three presentations were chosen for a final selection of the Final Oral Abstract Winner on the third day of the meeting.

Monday April 16th marked the first day of the CME program at *PICS~AICS*. The day started with a busy morning of live case transmissions from Petach Tikva, Israel, where Dr. E. Bruckheimer and his team performed three cases including implantation of a covered stent in a patient with Turner Syndrome and coarctation, percutaneous PV implantation using the Edwards - Sapien valve in a patient with TOF with 3DRA of the coronaries, as well as ASD closure using the Flex II Occlutech ASD occluder with 3DTEE evaluation of the defect. From Copenhagen, Denmark, Drs. O. Franzen & L. Sondergaard and their team presented 3 live cases of adults with structural heart disease including closure of an ASD using the Gore Helex Occluder device and the Occlutech device in a second case and an interesting case of transfemoral TAVI in an adult with severe AS using the CorValve. Finally that morning and live from Rome, Italy, Dr. G. Pongiglione and his team transmitted 2 live cases: hybrid stent placement and trans-apical PV implantation in a patient with TOF and pseudoaneurysm of the RVOT, and percutaneous PV implantation using the Edwards valve in a patient with TOF.

After the morning live case transmissions, the afternoon featured a total of five breakout sessions running simultaneously with extensive discussion of various topics. This new format adopted at *PICS* this year allowed coverage of multiple key topics and gave attendees the opportunity to attend what best fits their interests. The first session focused on Imaging in Congenital and Structural Cardiovascular Interventional Therapies (ICSCIT) directed by Dr. Girish Shirali. The role of various imaging techniques including TEE, ICE, CT, MRI, IVUS, 3D echo and 3D rotational angiography was discussed during this session. A notable lecture was presented by Dr. Craig Fleishman on imaging in hybrid procedures which are becoming more

commonly performed in complex cases and younger patients. The imaging session featured short case examples on the use of ICE vs TEE in ASD closure (Dr. A. Ludomirsky), echo-guided PDA closure (Dr. Neil Wilson), 3D TEE in ASD closure (Dr. David Roberson), rotational angiography for PA stenting (Dr. Evan Zahn), using micro TEE in ASD closure in adults (Dr. S. Qureshi), ICE in PV implantation (Dr. Q. Cao), intraop imaging for TAPVR (Dr. R. Siegel) and the use of IVUS in coarctation stenting (Dr. J. Cheatham).

Running simultaneously, the second breakout session was very well attended with a large audience and focused on neonatal cardiac catheterization. Topics included standardizing the risk in neonatal catheterization (Dr. Lisa Bergersen), catheterization in the premature or low birth weight infant (Dr. Neil Wilson), bedside atrial septostomy (Dr. Howard Weber), catheter management of the restrictive atrial septum in HLHS (Dr. D. Shranz), catheterization in neonates on ECMO (Dr. A. Javoix), balloon aortic valvuloplasty in critical AS (Dr. R. Rossi) and stenting of the PDA as an alternative to surgical Shunts (Dr. M. Alwi).

Another breakout session was dedicated to nurses and associated professionals and was led by Sharon Hill, Kathleen Nolan and Mary Heitschmidt. Topics discussed included: outcomes of interventional cath during pregnancy for mothers with CHD, emergencies in the cath lab, transcatheter PV replacement, overview on "valve clinic", research in pediatric and adult CHD, IMPACT registry, and radiation control protocols as well as the famous "Analyze This" session!

The last two sessions of that day focused on transcatheter aortic valve replacement, one of the most recent and revolutionary areas of research in the development of cardiovascular devices. The session discussed how to establish an aortic valve program, advanced imaging techniques pre- and post- TAVR and how to minimize vascular complications in TAVR. There was a discussion of 4 new valves available for TAVR (Colibri, St. Jude, Lotus and Jena valves). In addition, Dr. G. Fontana presented the results of the ADVANCE study for the Medtronic CoreValve and Dr. S. Kodali presented an update on the two-year follow-up data of the PARTNER I study mainly showing that TAVI in patients with severe aortic stenosis performed as well through 2 years as it did through the first year of the PARTNER trial, both among inoperable patients, as well as high-risk, but operable patients and hence supporting TAVR as an alternative to surgery in high-risk patients (defined as those with coexisting conditions putting them at a risk of death of at least 15% by 30 days after the operation). In addition, updates on the Edwards SAPIEN valve and its ongoing trials were presented. The issue of transfemoral vs transapical approach was also discussed in addition to the impact of TAVR on MV function (Dr. C. Kavinsky) and Valve-in-Valve Deployment (Dr. H. Sievert).

At the end of the day, Dr. Carlos Pedra presented the annual PICS Achievement Award to Dr. H. Faella from Argentina. It was a big surprise for Dr. Faella who had actually participated in all PICS meetings since its inception in Boston 1997! Congratulations Horacio!

The third day of the meeting started with more live case transmissions from Columbus, Chicago and Montreal. Drs. J. Cheatham and his team performed three live cases from Columbus: transcatheter PV implantation in a patient with TOF/PA s/p repair and using ICE and 3DRA imaging techniques, treating SVC stenosis and pulmonary vein stenosis and perventricular implantation of Melody TPV.

From Rush University in Chicago, Dr. Hijazi and the team performed interesting cases including transcatheter rehabilitation of the branch PAs in a patient with Williams Syndrome and an unusual case requiring stenting of the LMCA in a patient with William Syndrome (age about 4 years). These prompted discussions from the audience while performing the procedures live, highlighting the exceptional educational experience that the PICS meeting offers.

Finally, from Montreal, Dr. R. Ibrahim and his team transmitted live cases of PMVSD closure using the Amplatzer PMVSD II device, ASD closure using the Gore Septal Occluder and a case of percutaneous PDA closure in a premature newborn with trans-thoracic echo guidance.

The afternoon of the third day continued with the finals for oral abstracts followed by five breakout sessions. This included a session for the



young interventionalist group with a guest lecture on revascularization of thrombosed vasculature in pediatric patients by Dr. H. Justino, followed by the PICES meeting. This society, founded last year at PICS, has as a founding mission to support the clinical, and academic development of early career congenital interventionalists, and provide a networking opportunity to discuss clinical case challenges.

In addition, there was a session focusing on device closure of defects including discussion of topics such as PDA closure in adults, ASD closure using bioabsorbable devices and new devices for membranous VSD closure. This session featured an interesting discussion on device erosion after ASD closure with a panel discussion on the topic. Dr. W. Hellenbrand provided an update on the worldwide data on cases of erosion after ASD closure with the ASO from the SJM erosion board. It was felt that the cause is still unclear, and is probably multifactorial. The panel discussed the need to have a prospective registry whereby each case of ASD device closure in the US would be included and that can ultimately help define the exact risk factors associated with this complication. This panel discussion came timely just prior to the FDA panel discussion that took place in May after PICS.

Another simultaneous session focused on percutaneous mitral and tricuspid valve therapies.

Other discussions included what patients to avoid in percutaneous MV repair (Dr. S. Kar), update on the REALISM study (Dr. T. Feldman) and world experience in transcatheter TV replacement (Dr. E. Zahn).

The fourth breakout session on Tuesday brought a major up-to-date review on the options for stent implantation in CHD: the outcomes of the COAST II study (Dr. R. Ringel), treatment options for neointimal proliferation after stenting (Dr. F. Berger), evolving stent design (Dr. T. Forbes), pulmonary artery stenting in infants (Dr. P. Moore). This session ended with an interesting Hot Debate on Stenting the PDA/banding PAs as the first step for HLHS palliation (Pro: Dr. M. Galantowicz, Con: Dr. E. Bacha).

The last session on that long informative day featured the Heart Brain symposium and PFO summit, which was again coordinated between the PICS Foundation and the PFO Research foundation. Topics included discussion of device choice and when to intervene for residual shunting (Dr. H. Sievert), update on the PFO trials data (Dr. W. Budts), LAA occlusion (Dr. C. Pedra) and the influence of valve delivery approach on the incidence of stroke in TAVR (Dr. H. Figulla). The symposium ended with an interesting hot debate on whether the presence of migraine in patients with cryptogenic stroke should or should not influence the decision to close PFO (Pro: Dr. R. Cubeddu, con: Dr. M. Reissman).

At the end of the third day, the traditional PICS Gala dinner took place at the Museum of Science and Industry which opened its doors in 1933 and is the largest science museum in the Western Hemisphere! The evening event was well-attended, and gave colleagues an opportunity to share a relaxed, enjoyable night together.

The fourth and last day of PICS was busy and educational as well. Again, live case demonstrations took place in the morning. Dr. J. Carroll and his team from Denver, CO performed live cases including an interesting case of PFO closure in an adult with stroke and attempt to retrieve a previously placed HELEX device that embolized to the RPA, and a case of RPA stenting in an adult with RPA stenosis using 3D rotational angiography techniques.

From Seattle Children's Hospital, Dr. T. Jones and his team performed a case of transcatheter aortic valve implantation using the Melody valve in an adolescent with AS, closure of an aorto-RV shunt using the Amplatzer Duct Occluder under TEE guidance and transcatheter PV implantation using the Melody valve in a patient with TOF/PA s/p repair.

The didactic sessions on Wednesday took place in three separate breakout sessions that ran simultaneously. This included the traditional and popular "My Nightmare Case in the Cath Lab" which always provides an interesting review of some of the most challenging cases and experiences that colleagues have faced in the cath lab. Drs. Neil Wilson and Shak Qureshi did a fantastic job at moderating this session by involving the audience at various occasions making the session both educational and fun.

Simultaneously, a session on complex structural interventions was held discussing complex issues such as occlusion of coronary artery fistulae (Dr. D. Balzer), complications in stenting for coarctation in adults (Dr. E. Bruckheimer), LAA occlusion (Dr. K. Walsh), ruptured sinus of Valsalva occlusion (Dr. D. Hagler), hybrid approach for post-infarct VSD (Dr. Z. Amin) and occlusion of complex collaterals (Dr. F. Ing).

The last breakout session of PICS held on Wednesday was a comprehensive session with in-depth focus on pulmonary valve interventions. This included discussion of balloon pulmonary valvuloplasty (Dr. L. Latson), transcathether pulmonary flow restrictors (Dr. J. Cheatham), cutting balloon angioplasty in severe RVOTO (Dr. M. Gewillig), transapical implantation of the PV in small children (Dr. E.

"With the next PICS-AICS 2013 meeting coming sooner next year, January 19th-22nd, in Miami, Florida, planning is well under way and we look forward to another successful meeting!"

Zahn), advanced imaging after PVR (Dr. J. Vincent), CPET imaging after PVR (Dr. D. Kenny) and a review on the Melody and SAPEIN valves (Dr. K. Walsh).

Of course, continuing throughout the sessions at PICS were the highly popular Hot Debates! A total of nine such debates took place this year! These debates bring to the table an interesting and exciting discussion on topics that are presented from the point of views of the interventional cardiologist vs. the cardiothoracic surgeon. Interesting debates this year included one on RVOT Stenting vs Surgical Shunt in Neonates With Tetralogy of Fallot and Inadequate Pulmonary Blood Flow (Pro: Lee Benson vs Con: Emile Bacha), that featured a fun video presented by Dr. Benson featuring a sketch of the surgeon's way of thinking about the topic! Other interesting debates included discussion of device erosion after ASD closure (For: Michel Ilbawi; Against: John Bass); the use of Percutaneous Mitral Valve Therapies only in patients not suitable for surgical repair (For: Pat McCarthy; Against: Saibal Kar), stenting PDA/banding PA's as the first step for palliation of HLHS (For: Mark Galantowicz, Against: Emile Bacha), the Presence of migraine in patients with cryptogenic stroke and the decision to close PFO (Pro: Robert Cubeddu; Con: Mark Reisman), closing all VSD's adults irrespective of size (For: Mario Carminati; Against: Richard Ringel), amongst others.

The last day of *PICS* ended with roundtable discussions looking at interventional therapies in the developing world and the need for standards of care in interventional therapies. This also included interesting discussions on how interventionalists may get involved in coordinating mission trips to the developing world to help improve the delivery of interventional therapies for structural heart disease in these countries. The PICS Foundation will assume a large role in coordinating some of these missions.

PICS ended again with the Exhibit Passport drawing of the name of one lucky winner of a new iPAD who had visited all exhibits and stayed till the last minute of the meeting! This year's winner was from Birmingham Childrens Hospital, UK.

With the next *PICS-AICS 2013* meeting coming sooner next year, January 19th-22nd, in Miami, Florida, planning is well under way and we look forward to another successful meeting!. The online abstract submission site is open so make sure to send your abstracts before the deadline (September 15, 2012). Again, next year there will be a $5,000 scholarship awarded to the best scientific abstract submitted.

See you in the *Magic City* for another amazing, educational and fun symposium!! (For registration check the website at www.picsymposium.com.)

CCT

A special thanks to Dr. Qui Ling Cao for many of the photos used in this article.



Karim Diab, MD, FACC, FASE
Medical Editor, PICS Foundation and on behalf of all Course Directors and Co-directors

Children's Heart Center for Pediatric Cardiology
Phoenix Children's Hospital
1919 E. Thomas Rd.
Phoenix, AZ 85016
Tel: +(602) 933-3366
kdiab@phoenixchildrens.com

Congenital Cardiology Today Turns 10 Years Old and Introduces a Chinese Edition

By Tony Carlson; Richard Koulbanis; John M. Moore, MD

Congenital Cardiology Today (CCT) has come a longer way than most would imagine. It was originally conceived on the sidelines of the youth soccer fields in Potomac, Maryland USA in the late 1980's as two dads, Tony Carlson, a marketing executive specializing in high-tech custom publishing and John Moore, a pediatric cardiologist talked about their respective professions. John explained to Tony what a pediatric cardiologist does, how pediatric cardiology is a small sub-specialty that serves a relatively unique patient population of mostly children, but also some adults, with congenital and acquired heart disease. As an interventionalist, he talked about the technologies being used to treat patients. Tony provided John with details about technical journals and newsletters also arose from those talks: targeting technical audiences, monthly publications with short times to print, timely articles written by experts, news items of unique interest to the target audience, book reviews,new products, job opportunities,etc. As soccer season ended, the two dads, Dr. John Moore and Tony Carlson, concluded that pediatric cardiology would benefit from a technical publication of some sort.

Fifteen years later Tony, was running his own businesses, reminded Dr. John Moore about the publication which they had discussed years earlier. The idea still seemed like a good one, and they decided to "go for it." Tony found industry sponsors, and a publisher and editor, Richard Koulbanis. Tony and Richard had been in publishing together off and on for over 20 years, and Richard had held such positions as VP/Strategic Planning for Elsevier US Holdings, VP & Group Publisher, Senior VP/Research Publishing, and was now managing his own consulting business. Tony and Richard discussed just what type of publication would be best suited for this small close-knit medical community. They decided on a newsletter format. They then moved on to the tasks of creating a subscriber base, designing the publication and website, developing business, editorial and marketing plans, and deciding how the publication would be distributed. A subscriber list of over 2,000 pediatric cardiologists in the US and Canada was created from scratch. This whole process took another nine months before the launch in September of 2003.

The first monthly issue, *Pediatric Cardiology Today,* was published September 2003 and was distributed at the *PICS & ENTICHS* meeting in Orlando, Florida (USA). In 2005 the name of the publication was changed to *Congenital Cardiology Today* (CCT) because we expanded our editorial perview to include pediatric and adult cardiologists focused on congenital and structural heart disease.

As we attended various cardiology-focused meetings, many cardiologists from Europe and other parts of the world asked if CCT was published outside of North America. In response to those requests, CCT started publishing an International Edition in 2005 that now serves Europe, Latin/South America, Asia and the Middle East with over 1,500 readers. Now CCT has over 4,000 readers from around the world.

CCT offers one of the largest online live case video website libraries (www.CHDvideo.com) with over 300 live cases and presentations from world renown pediatric and adult cardiologists focused on congenital and structural heart disease with over 30,000 website visitors annually who watch the live cases and presentations.

Some of the Most Memorable Articles

- "Emerging Strategies in the Treatment of HLHS: Combined Transcatheter & Surgical Techniques" by Sharon Hill, ACNP, Mark Galantowicz, MD and John Cheatham, MD (November 2003).
- "Telemedicine Applications in Pediatric Cardiology" by Craig Sable, MD (July 2004).
- "Mechanical Circulatory Assist Devices in Children with Therapy-Refractory Heart Failure: A Review" by Felix Berger, MD and Brigitte Stiller (September 2005).
- "Noninvasive Monitoring of Cardiac Output: Benefits of NIRS Technology" by George Hoffman, MD and Nancy Ghanayem, MD (June 2007).
- "IMPACT Registry Prepares to Launch Pilot" Gerard Martin, MD (September 2009).
- "A New Study to Evaluate Destination Therapy in Failing Fontan Patients" by Timothy Ioenogle, MD and Alaxa Schmitt, PhD (October 2010).
- "Hand-Held/Pocket Echocardiography: Expanding Applications in Pediatric Cardiology" by Stephanie Lacey and Craig Sable, MD (October 2011).
- "Expanding the Role of Percutaneous Pulmonary Valve Implantation" by Sara Trucco, MD and Jacqueline Kreutzer, MD (April 2012).

In addition, the newsletter has carried summaries of important cardiology meetings, as well as important events like the Chuck Mullins Catheterization Laboratories dedication, passing of prominent colleagues and mentors, clinical trial information, new products, information and services, government and regulatory issues, and other newsworthy features.

Cover of the first Chinese edition of Congenital Cardiology Today. To view the issue, go to http://tinyurl.com/8j9etus

In August 2012 the first Chinese Language Edition of CCT was published in conjunction with Beijing Zenomed Scientific, Ltd. and distributed to over 2,000 pediatric cardiologists throughout China. The Editorial Board is headed by Dr. Ling Han.

Editorial Board For The Chinese Language Edition Includes:

- **Dr. Ling Han**, Director of Pediatric Cardiology Department in Beijing Anzhen Hospital of Beijing Capital Medical University, serves as the Deputy Leader of Chinese Medical Association Pediatric Division Cardiovascular Group. She is the Editor of the *Chinese Journal of Pediatrics,* the *Chinese Journal of Practical Pediatrics* and the *Chinese Pediatric Emergency Medicine.*
- **Dr. Shiliang Jiang**, Director of the Radiology Department of the Chinese Academy of Medical Sciences Affiliated Fu Wai Hospital, is the Director of the Radiographic Rresearch Center, and the Deputy Director of Interventional Treatment Ccenter. He is the Editor of the *Chinese Journal of Radiology,* the *Chinese Journal of Interventional Cardiology* and the *Journal of Clinical Radiology.* He serves as a committee member of the Beijing Branch of the Chinese Medical Association, and a member of the Interventional Radiological Group.

- **Dr. Junbao Du**, Deputy Director of the Department of Pediatrics, Peking University First Hospital. He serves as the leader of Chinese Medical Association Pediatric Division Cardiovascular Group, as the Deputy Editor-in-Chief of the *Chinese Journal of Pediatrics* and the *Chinese Journal of Practical Pediatrics.*
- **Dr. Yufen Li**, Director of Pediatric Cardiology Department in Guangdong Institute of Cardiovascular Disease, serves as the deputy leader of Chinese Medical Association Pediatric Division Cardiovascular Group. She is the Editor of the *Journal of Clinical Pediatrics.*
- **Dr. Kun Sun**, Head of Xin Hua Hospital affiliated to Shanghai Jiao Tong University School of Medicine, the President of Pediatrics Medicine School of Shanghai Jiao Tong University, the Director of Pediatrics Department of Shanghai Jiao Tong University School of Medicine. He serves as the deputy leader of the Chinese Medical Association Pediatric Division Cardiovascular Group, the Director of Shanghai Medical Association Pediatric Division, and the Deputy Director of Shanghai Medical Association Ultrasound Diagnosis Division. He specializes in diagnosis and interventional treatment of congenital heart disease.
- **Dr. Shengshou Hu**, Head of Fu Wai Hospital and the President of Institute of Cardiovascular Disease. He specialized in cardiovascular surgery for over twenty years. He serves as Executive Director of the Tissue Engineering Professional Committee of Biomedical Engineering Association, and as the Director of Chinese Medical Association Beijing Cardiovascular Surgery Division. Also, he is the Deputy Editor-in-Chief of the *Chinese Journal of Clinical Thoracic and Cardiovascular Surgery*, the Editor of the *Chinese Journal of Minimally Invasive Surgery,* the *Chinese Journal of Cardiology,* and the *Chinese Circulation Journal.*
- **Dr. Jinfen Liu**, Head of Shanghai Children's Medical Center. He is a member of the World Pediatric and Congenital Heart Disease Association, member of American Association of Cardiovascular Surgery, the leader of Chinese Pediatric Surgery Association Cardiothoracic Surgery Group, and a committee member of Chinese Cardiothoracic Surgery Association of the Shanghai Branch. He is a pediatric heart surgeon and also the Editor of the *Chinese Journal of Thoracic and Cardiovascular Surgery,* the *Chinese Journal of Pediatric Surgery,* and the *Journal of Clinical Pediatrics and World Journal of Pediatrics.*
- **Dr. Jian Zhuang**, Head of Guangdong General Hospital and the Director of the Cardiac Surgery Department. From 1996 to 1997 he was a visiting scholar of the Cardiovascular Surgery Department at the Queen's Medical Center in Honolulu, Hawaii, USA. He serves as the Deputy Director of Chinese Medical Association Thoracic and Cardiovascular Surgery Division, the Director of Guangdong Medical Association Thoracic and Cardiovascular Surgery Division, the Vice President of Chinese Medical Doctor Association Cardiac Surgery Doctor Division, the Deputy Editor-in-Chief of the *Chinese Journal of Thoracic and Cardiovascular Surgery.*

Congenital Cardiology Today is proud to serve the dedicated pediatric and adult cardiologists who focus on congenital and structural heart disease. These cardiologists with their special expertise for diagnosis and treatment, have helped, and continue to help, countless congenital and structural heart disease patients around the world. www.CongenitalCardiologyToday.com.

CCT

Tony E. Carlson
Founder, President & Senior Editor
Congenital Cardiology Today
PO Box 444
Manzanita, OR 97130 USA
T: +1.301.279.2005; F: +1.240.465.0692
TCarlsonMD@gmail.com

Richard Koulbanis
Group Publisher & Editor-in-Chief
Congenital Cardiology Today
Editorial Offices
Westerly, RI 02891 USA
RichardK@CCT.bz

John W. Moore, MD, MPH
Professor of Pediatrics
Chief, Section of Cardiology
Department of Pediatrics
UCSD School of Medicine
Director, Division of Cardiology
Rady Children's Hospital
3020 Children's Way, MC 5004
San Diego, CA 92123 USA

Medical News, Products and Information

Digisonics Customers Enhance Structured Reporting Systems to Add Web-based Remote Reading

Driscoll Children's Hospital in Corpus Christi, Texas and Pediatrix in Sunrise, Fla. have enhanced their Digisonics PACS and Structured Reporting Systems for cardiovascular and OB/GYN studies, respectively, by adding fully-functional web-based reading applications. Clinicians will have secure web-based access to the complete PACS and structured reporting system to review study images and create a professional report from anywhere at any time via the Internet.

The DigiView Cardiology PACS and Structured Reporting System, was ranked Best in KLAS in the 2008, 2009, 2010 and 2011 Top 20 Best in KLAS Awards. The Digisonics PACS and Structured Reporting Systems combines high performance image review workstations, a powerful PACS image archive, an integrated clinical database, comprehensive measurements and calculations package, and is highly configurable reporting for cardiovascular modalities. The DigiNet Pro add-on option provides users with fully functional web-based access to their cardiovascular studies from anywhere at any time.

The OB-View Image Management and Reporting System combines high-performance image analysis, PACS image archive, integrated clinical database, comprehensive fetal growth analysis and automated growth curves, and professional, concise reporting into one complete system. An additional OBLink interface provides autopopulatation of reports with patient demographics and measurements, saving data entry time and eliminating entry errors. Users will also have fully functional web-based access to their OB/GYN studies for image review and report editing via OB-View Net. For further information, go to: www.digisonics.com.

Medtronic Begins Global Clinical Trial Evaluating CoreValve® System Implantation in Intermediate-Risk Patients

In July, Medtronic, Inc. announced the first patient enrollment in a global, multicenter, randomized clinical trial comparing the Medtronic CoreValve® System with surgical aortic valve replacement in patients with severe aortic stenosis who are at intermediate risk to undergo open-heart surgery. The trial, called Medtronic CoreValve Surgical Replacement and Transcatheter Aortic Valve Implantation (SURTAVI) Trial, will evaluate the potential for the minimally-invasive CoreValve System to be considered for less-sick patients who typically are treated with open-heart surgical aortic valve replacement (SAVR) today.

The first patient procedures in the SURTAVI trial occurred at Rigshospitalet Copenhagen University Hospital in Copenhagen, Denmark, and were performed by Lars Søndergaard, MD, interventional cardiologist, and Daniel Steinbrüchel, MD, DMSc, cardiaothoracic surgeon.

"Transcatheter aortic valve replacement is a transformational, potentially lifesaving technology that typically is used to treat inoperable patients or patients for whom surgery carries high risks," said Patrick Serruys, MD, PhD, Professor of Medicine and Head of the Department of Interventional Cardiology at Erasmus Medical Center in Rotterdam, The Netherlands, and chairman of the SURTAVI trial. "The SURTAVI trial will offer guidance on how to best treat intermediate risk patients and may substantiate the CoreValve System as an attractive alternative treatment for these patients."

The Trial will be the largest global, randomized, controlled trial on transcatheter aortic valve implantation (TAVI) and will nominally evaluate approximately 2,500 patients at up to 75 clinical sites with experienced heart teams that include interventional cardiologists and cardiac surgeons. The trial will evaluate whether the CoreValve System is non-inferior to surgical valve replacement, based on the composite primary endpoint of all-cause mortality and major stroke at 24 months. Medtronic is working with the US FDA to include US patients in the trial.

Patients considered for the trial include those with severe, symptomaticaortic stenosis who are classified as intermediate surgical risk, as defined by a Society of Thoracic Surgeons' (STS) mortality risk of ≥ 4% and ≤ 10%. Patients will be randomized on a 1:1 basis to either TAVI with CoreValve or to surgery. CoreValve implantation can be performed by transfemoral, subclavian or direct aortic access, depending on the needs of the patient. All patients will be followed through five years.

"We are pleased to begin this important trial that may demonstrate the benefits of the CoreValve System in a broader population of patients with severe aortic stenosis," said A. Pieter Kappetein, MD, PhD, principal investigator of the SURTAVI trial and Professor of Cardiothoracic Surgery at Erasmus Medical Center in Rotterdam, The Netherlands. "This study represents a significant opportunity to bring a new therapy to physicians and a large percentage of patients, both of whom are looking for a less invasive option to treat aortic stenosis."

The Medtronic CoreValve System received CE (Conformite Europeenne) Mark in 2007. The CoreValve System is available in three sizes (26mm, 29mm and 31mm), and is the only transcatheter aortic valve implantation system approved for implantation via the direct aortic approach and the subclavian approach. The CoreValve System is currently limited to investigational use in the United States.

For more information go to www.medtronic.com.

The Society of Cardiovascular Computed Tomography (SCCT) Has Announced the Recipients of the 2012 TOSHIBA Young Investigator Award (YIA)

The Society of Cardiovascular Computed Tomography announced the recipients of the 2012 Toshiba Young Investigator Award, which were recently presented at the society's July 2012 *7th Annual Scientific Meeting* (SCCT2012), in Baltimore, Maryland. Supported by an educational grant from Toshiba America Medical Systems, Inc., the YIA Program is designed to promote the research, writing and oral presentation skills of those who are within five years of completing a training program. In addition, the program may provide the catalyst for some trainees to become future thought leaders in the field of cardiovascular imaging.
Each applicant submitted a mini-manuscript of 1,000 words concerning research related to the technical and clinical advancement of cardiovascular CT. Five finalists were selected to give an oral presentation at SCCT2012. All five finalists will be granted a complimentary SCCT membership for one year.

Of the finalists, three recipients have been recognized. This year's YIA Program recipients are:

- **Marcelo Nacif, MD, PhD**
  Radiology and Imaging Sciences - National Institutes of Health Clinical Center, Bethesda, MD, USA
  3D Left Ventricular Extracellular Volume Fraction by Low Radiation Dose Cardiac CT: Assessment of Interstitial Myocardial Fibrosis
- **Daniel Obaid, MD**
  University of Cambridge, Cambridge, United Kingdom
  Identification of Vulnerable Coronary Plaque Using Single and Dual Energy CT - Verification Against Histology and VH-IVUS
- **James Otton, MBBS, MBiomedE**
  St Vincent's Hospital, Sydney, Australia
  Four-Dimensional Image Processing of Myocardial CT Perfusion for Improved Image Quality and Noise Reduction

The other two finalists for this year's YIA Program are:

- **Marcio Bittencourt, MD**
  Brigham and Women's Hospital, Boston, MA, USA
  Coronary CT Angiography for Prediction of All-Cause Mortality
- **Stefan Sawall**
  Institute of Medical Physics, Friedrich-Alexander-University of Erlangen-Nürnberg, Erlangen, Germany
  Low-Dose Cardiac- and Respiratory-Gated Myocardial Perfusion Imaging of Free-Breathing Mice

"Toshiba is focused on developing advanced imaging technology and believes in supporting residents and fellows who are innovators in their field," said Doug Ryan, VP, Marketing & Strategic Development, Toshiba. "Toshiba and SCCT are committed to supporting the development and education of the young investigators, as they are the cardiovascular CT imaging leaders of the future."

For more information, visit the SCCT at www.SCCT.org, or Toshiba America Medical Systems, Inc.at www.medical.toshiba.com.

Advanced Visualization Techniques Could Change the Paradigm for Diagnosis and Treatment of Heart Disease

Newswise — Researchers from Mount Sinai School of Medicine are pioneering new ultrasound techniques that provide the first characterization of multidirectional blood flow in the heart. By focusing on fluid dynamics – specifically, the efficiency with which blood enters and exits the heart's left ventricle – the researchers believe they can detect heart disease even when traditional measures show no sign of trouble.

In addition to improving diagnoses, this shift in focus from muscle mechanics to fluid mechanics could lead to more effective therapeutic interventions. The work is described in a study published by two Mount Sinai cardiologists and a team of international collaborators in a recent issue of *JACC Cardiovascular Imaging*, a journal of the American College of Cardiology.

The ultrasound tools cardiologists use today often fail to detect changes in the heart until there is overt dysfunction. Blood flow imaging, however, may provide better clues in diagnosing heart failure. Sinai investigators reason that flow should be immediately affected by changes in cardiac function – such as those revealed in image analysis by the chaotic behavior of tiny whirlpools.

The computer-aided visual study of these abnormalities could dramatically improve the assessment of patients with heart failure and lead to a fresh understanding of normal and abnormal pumping and circulatory function. Visual blood-flow analysis could also yield improved therapies for arrhythmias and other disorders requiring cardiac synchronization. Researchers are actively exploring applications in aortic atherosclerosis, before and after valve replacement, and congenital abnormalities.

"With visualization, we are looking at the ultimate measure of the efficiency of the heart – how the blood is brought in and how it is sent out," said Jagat Narula, MD, PhD, Director of Cardiovascular Imaging at Mount Sinai and the senior author of the paper. "Today, cardiologists place great weight on a gauge called the squeeze fraction, or ejection fraction – the portion of blood pumped from the ventricle with each heartbeat. What we are doing is a complete departure from the view of the heart as a squeezing, pressure-generating chamber."

Mount Sinai researchers and their collaborators have experimented with a range of imaging techniques to grasp the characteristics of normal and abnormal blood flow. The approaches include phase-encoded MRI, cardiac magnetic resonance (CMR) and several forms of ultrasound-based imaging known as echocardiographic particle imaging velocimetry.

"The most effective technique involves injecting a stream of bubbles that behave exactly like red blood cells and using echocardiography to track their path through the left ventricle," said Partho Sengupta, MD, Director of Cardiac Ultrasound Research at Mount Sinai, and the first author, with Narula, of the JACC paper. In these investigations, the computer-enhanced video output depicts normal and turbulent flow in vivid detail, with arrows plotting the direction as the bubbles swirl through the heart chamber.

"Not only are you following the path of the blood, but you can actually identify the amount of energy that is being distributed," said Dr. Sengupta. "Like other forms of ultrasound, that means low-cost heart tests using this technology could be performed on a simple outpatient basis."

The echocardiography technology pioneered by Sengupta and Narula sheds light on diagnostic discrepancies that have puzzled cardiologists relying on pressure measurements.

"After sustaining significant damage, a patient's heart may not have the greatest squeeze, but there could be good trafficking of blood through the heart and the patient could remain asymptomatic," Sengupta explained. "The normal ejection fraction is around 60%, but we sometimes see a patient with 20% walking around and playing golf. Other people who are at 50% may be short of breath. Flow visualization is one way to capture the essence of why the patient is or is not symptomatic."

"Diagnosing cardiac disease by looking for structural defects in the heart is like analyzing highway traffic by examining the road," Dr. Narula said. "The structure may not be great, but how does that affect the cars that are actually traveling on the road? It's the same thing if you fail to look at the blood."

Likewise, a plumber's investigation of pipes in a house only matters or makes sense in relation to how the water flows, claims Sengupta. A new study these investigators have submitted for publication zeros in on specific correlations between blood flow and cardiac pathology. "We will be able to demonstrate that efficiency may be lost even though the structure is maintained," said Senguptra. "In other words, the façade is good, but inside, you have lost it."

Sengupta points out that the combined visualization and computation techniques in the JACC paper are still new and require further work, including development of appropriate flow-based indexes for applications in various cardiac pathologies. Forces acting on flow are exceedingly complex and dynamic, the researchers said. Pumped by the heart at a rate of 8 pints to 16 pints per minute, blood interacts with the contours of the myocardium, valves, vessels, and other features, which are also in motion. The flow is multidirectional – curling, spinning, and forming eddies that are affected in countless ways by structural changes in heart tissue. As with any new observational techniques, data from novel cardiac visualizations in complex environments are subject to interpretation.

"We have started using these imaging techniques in clinical trials," Narula said. "They will require careful evaluation."

The Mount Sinai Medical Center encompasses both The Mount Sinai Hospital and Mount Sinai School of Medicine. Established in 1968.
For more information, visit www.mountsinai.org.

Skewed Results? Failure to Account for Clinical Trial Drop-Outs Can Lead to Erroneous Findings in Top Medical Journals

Newswise - A new University at Buffalo study of publications in the world's top five general medical journals finds that when clinical trials do not account for participants who dropped out, results are biased and may even lead to incorrect conclusions.

Published recently in the *British Medical Journal*, the methodological study consisted of a systematic analysis of 235 clinical trials published in the world's top five general medical journals between 2005 and 2007 that claimed a statistically significant effect.

"We found that in up to a third of trials, the results that were reported as positive – in other words, statistically significant – would become negative – not statistically significant, if the investigators had appropriately taken into consideration those participants who were lost to follow-up," says Elie A. Akl, MD, MPH, PhD, lead author, and Associate Professor of Medicine, Family Medicine and Social and Preventive Medicine at the University at Buffalo School of Medicine and Biomedical Sciences and School of Public Health and Health Professions. He also has an appointment at McMaster University.
"In other words, one of three claims of effectiveness of interventions made in top general medical journals might be wrong," he says.

In one example, a study that compared two surgical techniques for treating stress urinary incontinence found that one was superior. But in the analysis published this month, it was found that 21% of participants were lost to follow-up. "When we reanalyzed that study by taking into account those drop-outs, we found that the trial might have overestimated the superiority of one procedure over the other," Akl says.

According to Akl, it has always been suspected, but never proven, that loss to follow-up introduces bias into the results of clinical trials. "The methodology we developed allowed us to provide that proof," he says.

The methodology that he and his coauthors developed consists of sensitivity analyses, a statistical approach to test the robustness of the results of an analysis in the face of specific assumptions, in this case, assumptions about the outcomes of patients lost to follow-up.

"This study gives us a better understanding of the problem of loss to follow-up in clinical trials and provides us with better tools to address it," Akl says.

"This methodology will allow those who conduct the trials and those who use their results, including clinicians, other scientists, developers of clinical guidelines, policymakers and bodies like the Food and Drug Administration, to better judge the risk of bias," concludes Akl.

The studies that were analyzed had previously been published in *Annals of Internal Medicine, British Medical Journal, the Journal of the American Medical Association, Lancet* and the *New England Journal of Medicine*. To be included, the trials that were studied had to have reported a significant effect.

Akl led this major study, which took three years to complete. His co-authors, 20 clinical epidemiologists, are from the following institutions: McMaster University; University Hospital Basel; Kaiser Permanente Northwest; Hospital for Sick Children in Toronto; Institute for Work and Health, Universitè de Sherbrooke; University Children's Hospital Tuebingen; Pontificia Universidad Catolica de Chile; Tel Aviv University; the University of Ottawa; the University of Freiburg and the University of Oxford.

CONGENITAL CARDIOLOGY TODAY

Publication Headquarters: 8100 Leaward Way, Nehalem, OR 97131 USA
Mailing Address: PO Box 444, Manzanita, OR 97130 USA
Tel: +1.301.279.2005; Fax: +1.240.465.0692
Editorial & Subscription Offices: 16 Cove Rd, Ste. 200, Westerly, RI 02891 USA

www.CongenitalCardiologyToday.com

SIZING UP THE FUTURE

X™ Line PTV Balloon Dilatation Catheters

Braided inner tubing and radiopaque marker bands for maintaining strength & trackability

PTS® Sizing Balloon Catheters

For accurate measurement of selecting the appropriately sized occluder device

NuCLEUS-X™

PTV Balloon Dilatation Catheters

Variable waist expansion in the center of the balloon for accurate placement

B|BRAUN Interventional Systems

B. Braun Interventional Systems Inc.
824 Twelfth Avenue
Bethlehem, PA 18018
Tel: 1-877-VENA CAV (836-2228)
Fax: 610-266-3982

www.bisusa.org