



April 2019 - Volume 17 - Issue 4
North American Edition

Inside This Issue

Treatment Options for Severe Functional Tricuspid Regurgitation: Indications, Techniques and Current Challenges

By Christian Besler, MD; Joerg Seeburger, MD;
Seeburger, MD; Holger Thiele, MD;
Philipp Lurz, MD, PhD - p. 1

Transition of Care for Congenital Heart Patients: Challenges, Opportunities, and Pathways for Providers

By Wayne J. Franklin, MD - p. 10

9th Annual Phoenix Fetal Cardiology Symposium Summary

By Chris Lindblade, MD - p. 14

Medical News, Products & Information - p. 15

Upcoming Medical Meetings

International PDA Symposium 2019

Apr. 10-12, 2019; Memphis, TN, USA
www.pdasymposium.org

40th Heart Rhythm Scientific Sessions

May 8-11, 2019; San Francisco, CA, USA
www.heartrhythmssupport.org

53rd Annual Meeting of the Association for European Paediatric and Congenital Cardiology

May 15-18, 2019; Seville, Spain
www.aepc2019.org

SCAI 2019 Scientific Sessions

May 19-22, 2019; Las Vegas, NV, USA
www.scai.org/scai-2019-scientific-sessions

AI Med Cardiology

Jun. 17-18, 2019; Chicago, IL, USA
www.aimed.events/aimed-cardiology-2019/

Corporate Office

11502 Elk Horn Drive
Clarksburg, MD 20871 USA

www.CongenitalCardiologyToday.com

 @ccardiology

Official publication of the CHiP Network

Treatment Options for Severe Functional Tricuspid Regurgitation: Indications, Techniques and Current Challenges

By Christian Besler, MD; Joerg Seeburger, MD;
Holger Thiele, MD; Philipp Lurz, MD, PhD

Topic(s): Interventional Cardiology and Cardiovascular Surgery, Valvular Heart Disease

Severe functional tricuspid regurgitation represents an important unmet need in clinical cardiology given its prevalence, adverse prognostic impact and symptom burden. Surgical tricuspid valve annuloplasty remains the treatment of choice for the majority of patients, especially if the operative risk is acceptable and preserved right ventricular function is present. However, several transcatheter techniques are currently in bench and early clinical testing to provide alternative treatment options for patients with a very high surgical risk. Future trials are needed to address the question as to whether transcatheter treatment of tricuspid regurgitation improves long-term prognosis and is superior to medical treatment alone in these patients.

Keywords: Pulmonary hypertension, right ventricle, transcatheter therapy, tricuspid regurgitation, tricuspid valve

Introduction

Tricuspid regurgitation (TR) is an important, yet often underappreciated, disease in cardiology practice. In up to 90% of patients in Western countries, moderate-to-severe TR is secondary or functional, most often due to left-sided heart disease and other causes of pulmonary hypertension¹. In these cases, functional TR results from tricuspid annular dilatation in the

setting of right ventricular remodeling, mainly due to pressure or volume overload (Figure 1). Up to 50% of patients undergoing mitral valve surgery for functional ischaemic mitral regurgitation have moderate or severe TR, and a substantial proportion of patients develop TR late after previous left-heart surgery². Given the overall increase in life expectancy, improved treatment options for patients with ischaemic or non-ischaemic cardiomyopathy and expanding transcatheter interventions for mitral valve pathologies in patients at increased surgical risk, the number of patients presenting with relevant TR may increase in the coming decades. Importantly, recent publications have challenged the long-held misperception that functional moderate-to-severe TR will resolve once successful treatment of mitral regurgitation has been carried out. About 70% of patients with a more than moderate TR before mitral valve edge-to-edge repair still had moderate-to-severe TR after two years of follow-up³. The prevalence of coexisting moderate-to-severe TR is between 11% and 26% in patients undergoing Transcatheter Aortic Valve Replacement (TAVR) for native aortic valve stenosis, and a reduction in echocardiographic TR grade has been observed in 15% to 50% following TAVR in these patients⁴. Conflicting results have been reported regarding the prognostic impact of TR following TAVR and surgical aortic valve replacement. Interestingly, a recent analysis in patients at high surgical risk undergoing valve-in-valve TAVR for degenerated surgical aortic bio-prosthesis suggested a significant reduction in TR severity and lack of prognostic impact of preprocedural TR at short- and long-term follow-up⁴.

Recruit with CCT

Recruitment advertisements are listed

- In print and electronic monthly issue
- On our website
- In our monthly email blast



Contact: Kate@cct.bz

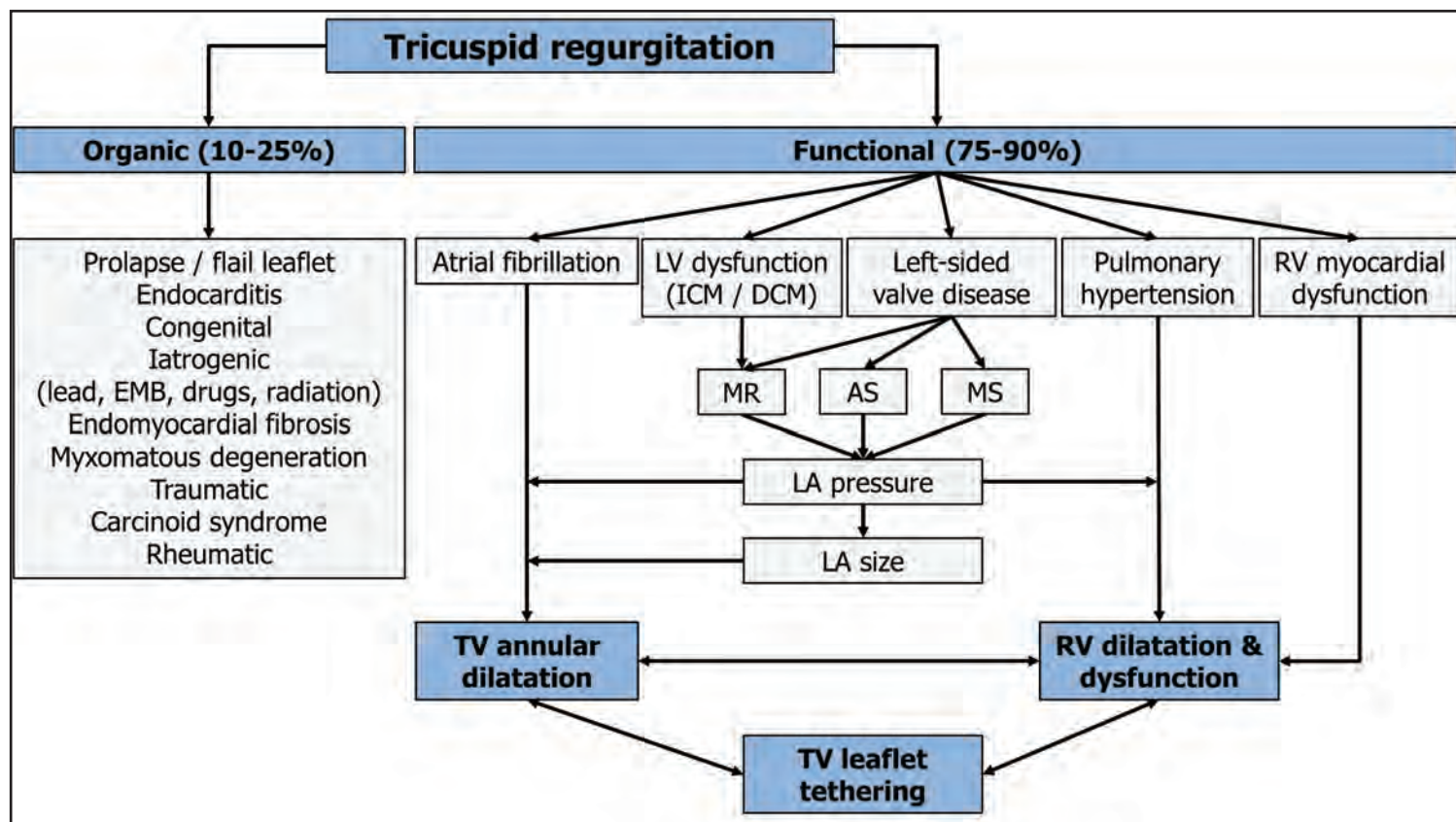


Figure 1. Causes of Organic and Functional TR. AS: aortic stenosis; DCM: dilated cardiomyopathy; EMB: endomyocardial biopsy; ICM: ischaemic cardiomyopathy; LA: left atrial; LV: left ventricular; MR: mitral regurgitation; MS: mitral stenosis; RV: right ventricular; TV: tricuspid valve.

Medical Treatment Options for Functional TR

Frequently, patients with moderate-to-severe TR present late in the natural history of the disease with exercise limitation and other symptoms of right heart failure difficult to treat by medical therapy. In the diagnostic and treatment process, the underlying cause of functional TR needs to be identified and treated, if possible. Patients with ischaemic or non-ischaemic cardiomyopathy are managed according to current heart failure guidelines⁵. If there is clinical suspicion of pulmonary hypertension, further differential diagnosis, including right heart catheterisation, is mandatory to classify pulmonary hypertension and identify patients who might benefit from specific drug therapy (e.g., calcium channel blockers, endothelin receptor antagonists, phosphodiesterase type five inhibitors and guanylate cyclase stimulators, prostacyclin analogues and prostacyclin receptor agonists). Oral anticoagulation should be initiated in patients with right heart chamber dilatation due to (repeated) pulmonary embolism. Nevertheless, in a considerable number of patients, medical treatment options of TR are limited for the following reason: often, an impairment of kidney function in patients with advanced TR limits further escalations of the diuretic dose to improve symptoms of volume overload. If kidney function is

preserved, adding an aldosterone antagonist represents a possible treatment option, in particular for patients with hepatic congestion and secondary hyperaldosteronism. However, the benefit either of aldosterone antagonists or of angiotensin-converting enzyme inhibitors/angiotensin II receptor blockers on right ventricular remodeling or functional improvement in patients with severe functional TR has not been validated in clinical studies.

Current Indications for Surgical Treatment of Functional TR

Current guidelines for the management of valvular heart disease provide recommendations to guide surgical interventions in primary and secondary TR⁶. Endorsements on transcatheter techniques targeting TR are not yet available, owing to the fact that interventional TR treatment is still in early clinical testing. The optimal timing of surgical intervention for TR remains controversial. However, delayed surgery must be avoided given the risk of irreversible right ventricular damage, organ failure and poor results of later surgical intervention. The 2017 ESC/EACTS Guidelines for the management of valvular heart disease provide a Class I (level of evidence: C) recommendation for tricuspid valve surgery in patients with severe functional TR undergoing left-sided

valve surgery⁶. Concomitant treatment of TR during left-sided heart surgery does not confer an increased risk of postoperative morbidity, mortality or permanent pacemaker requirement. According to a recent meta-analysis, concomitant tricuspid valve repair during left-sided valve surgery was associated with a reduction in cardiac-related mortality and improved echocardiographic outcomes for TR after a mean-weighted follow-up of six years as compared to cases without concomitant tricuspid valve repair⁷. A class IIa (level of evidence: C) recommendation is given for tricuspid valve surgery in patients with mild or moderate functional TR with a dilated tricuspid annulus (i.e., ≥ 40 mm or >21 mm/m² by 2D echocardiography) undergoing left-sided valve surgery⁶. The latter recommendation justifying tricuspid valve surgery in patients with moderate or even mild TR appreciates the increased risk of progressive TR and right heart failure once tricuspid annular dilatation has occurred. Tricuspid valve surgery may be considered in patients undergoing left-sided valve surgery with mild or moderate secondary tricuspid regurgitation even in the absence of annular dilatation when previous recent right heart failure has been documented (Class of recommendation: IIb, level of evidence: C)⁶. In addition, the guidelines provide a class IIa (level of evidence: C) recommendation for tricuspid valve surgery in patients

with severe TR after previous left-sided surgery if patients are symptomatic, or progressive right ventricular dilatation or dysfunction is evident. However, before a decision is made for re-operation on the tricuspid valve in cases of persistent TR after left-sided heart surgery, recurrent left-sided valve dysfunction, severe right or left ventricular dysfunction, and severe pulmonary vascular disease or hypertension have to be ruled out.

Surgical Repair Techniques for Functional TR

Surgical tricuspid valve repair with annuloplasty is the preferred treatment for functional TR in patients with suitable anatomy, preserved right ventricular function and acceptable surgical risk^{6,8}. Tricuspid valve annuloplasty techniques aim to target the pathophysiological hallmark of functional TR, i.e., dilatation of the tricuspid annulus mainly along its posterior portion with an increased size of the tricuspid valve orifice and alterations of annular geometry. Since the 1960s, several surgical annuloplasty methods have been described, including suture, band and ring techniques. Amongst them, suture bicuspidization, better known as the Kay procedure, is designed to reduce TR by obliterating the annular segment corresponding to the posterior leaflet through placement of pledget-supported mattress sutures in the annulus⁹. As a result, the tricuspid annular circumference is reduced, and the tricuspid valve is converted into a smaller but competent mitral-like valve. During De Vega annuloplasty, two C-shaped suture lines are placed along the base of the anterior and posterior tricuspid valve leaflet, starting at the anteroseptal commissure and ending beyond the origin of the coronary sinus. At the anteroseptal and posteroseptal commissures, the sutures lines are anchored with pledgets and, finally, tied to reduce the tricuspid valve orifice diameter⁹.

Currently, tricuspid valve annuloplasty is usually performed by implantation of an undersized ring (rigid, semi-rigid, flexible) or a flexible band (Figure 2). Compared with the use of flexible annuloplasty bands, implantation of a rigid or semi-rigid ring is associated with a reduced incidence of late, recurrent tricuspid regurgitation. However, use of a rigid ring may increase the risk of subsequent ring dehiscence¹⁰. Annuloplasty rings or bands do not cover the whole

tricuspid annulus, but remain open at the septal annulus to avoid injury to the conduction system. In recent years, refined tricuspid annuloplasty rings resembling the complex three-dimensional configuration of the native tricuspid annulus have been developed⁹. Retrospective analyses have suggested that ring annuloplasty is superior to suture annuloplasty in terms of residual and recurrent TR, redo surgery and, possibly, survival⁹. The choice of annuloplasty ring (rigid vs. flexible vs. three-dimensional) for tricuspid valve repair is still a matter of debate.

Tricuspid valve repair is associated with lower perioperative mortality as compared to valve replacement in patients with functional TR and, therefore, is generally the preferred surgical treatment option⁸. Tricuspid valve replacement should be considered when valve repair is technically not feasible or predictably not durable (e.g., in patients with profound right ventricular remodeling or dysfunction, or higher pulmonary artery pressures). Studies comparing bioprosthetic and mechanical valves for tricuspid valve replacement indicated similar long-term outcomes. Given the lower risk of thromboembolism, many surgeons favour bioprosthetic valves; however, the choice of prosthesis type should be individualized, taking into consideration the patient's age, condition, and concomitant cardiac or non-cardiac diseases⁹.

Limitations for Surgical TR Repair in Clinical Practice

Concomitant tricuspid valve repair for functional TR at the time of left-sided valve surgery is not associated with increased mortality if right ventricular function and dimensions are preserved and the patient does not suffer severe heart failure. However, repeat surgery for symptomatic TR late after left-sided valve surgery is associated with substantially increased perioperative morbidity and mortality, with early mortality rates up to 20% even in experienced centres. The increased risk of reoperation on the tricuspid valve has been attributed mainly to the late referral and consequently poor clinical condition of the patient. In these cases, the risk of repeat surgery has to be weighed against the modest functional outcome observed in many patients and the comprehensive preoperative evaluation of

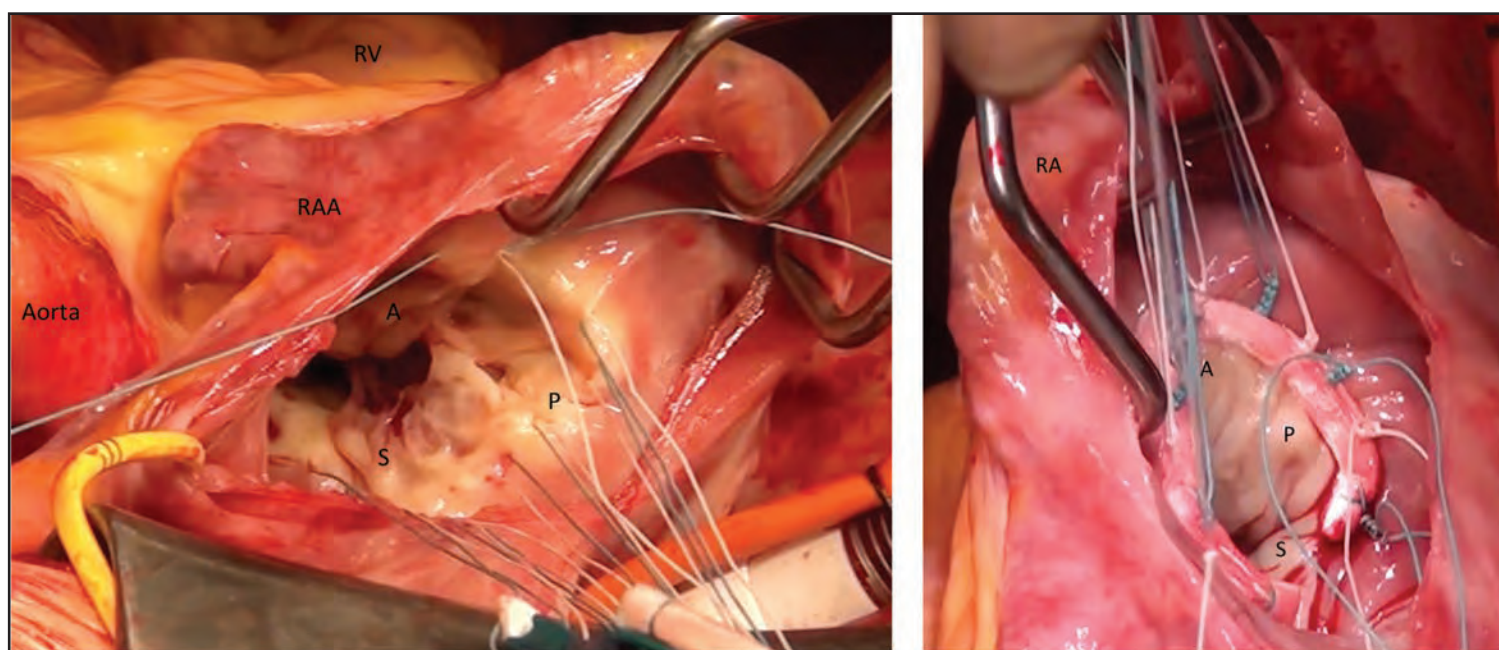


Figure 2. Intraoperative Surgical View of the Tricuspid Valve. Left: Annuloplasty ring sutures are placed along the annulus of the tricuspid valve starting from the septal leaflet (S), across the posterior part of the annulus (P) followed by the anterior (A).

Right: Implantation of an annuloplasty ring into the tricuspid valve. The septal annulus remains uncovered to avoid passing the anchoring sutures close to the conduction system. RA: right atrium; RAA: right atrial appendage; RV: right ventricle.

Procedural aspects	Surgical TVR	Transcatheter TVR
Acute and midterm procedural success	+	-
Data on long-term durability	+	-
Operative risk in elderly patients	substantial	low
Feasible in advanced RV failure	+	-
Widespread use/availability	+	-
Invasiveness of the procedure	-	+
Feasible despite impaired echo imaging	+	-

Table 1. Comparison of procedural aspects between surgical and transcatheter tricuspid valve repair. "+" indicates an advantage and "-" indicates a disadvantage of surgical or transcatheter TVR. RV: right ventricular; TVR: tricuspid valve repair.

left and right ventricular function, pulmonary hypertension, kidney and liver function. Minimally invasive tricuspid valve operations through a right thoracotomy may provide an alternative surgical treatment option associated with excellent early outcome, even in high-risk patients undergoing elective reoperative tricuspid valve repair for TR after left-sided heart surgery¹¹.

However, based on our own observations in clinical practice, there is yet another growing group of elderly patients presenting with massive TR and intractable symptoms of right heart failure without prior left-sided heart surgery. The clinical features of these patients are rather heterogeneous, but almost all of them display functional TR, about one third have an ejection fraction <40%, severe mitral regurgitation is seen in about 60% and there is a high prevalence of atrial fibrillation^{12,13}. Often, right heart chambers and tricuspid annulus are severely dilated, and right ventricular function is frequently impaired in this group of patients. In addition, a significant proportion of these patients display pacemaker or implantable cardioverter-defibrillator leads across the tricuspid valve, chronic pulmonary disease, pulmonary hypertension and an impairment in kidney function. These patients are highly symptomatic, with more than 95% presenting in NYHA functional Class III or IV despite optimal medical therapy, and face recurrent hospitalisations for decompensated right heart failure. Up until recently, conventional and/or minimally invasive tricuspid valve surgery was offered to these patients next to medical treatment, however, at a significant operative risk. Nowadays, emerging transcatheter therapies may provide an alternative treatment option for these patients if surgical risk exceeds the potential benefit.

Emerging Transcatheter Treatment Options for Functional TR

In recent years, several devices have entered preclinical and early clinical testing for transcatheter treatment of functional TR. Overall, the number of patients treated in compassionate use or clinical feasibility programmes is still limited and data on long-term haemodynamic consequences are missing. Nevertheless, early signs of safety, feasibility and clinical benefit for some devices have aroused great interest among cardiac specialists. Current studies aim to address the question whether interventional TR treatment provides an alternative therapeutic option for patients with severe functional TR, intractable symptoms of right heart failure and prohibitive surgical risk based on the conclusive decision of a multidisciplinary Heart Team (Table 1). Current existing transcatheter therapies for functional TR can be divided into three groups according to their mode of action and anatomic therapeutic target (Figure 3). The present article provides a short summary of devices which have been applied in patients with severe functional TR and for whom published data (at least case records) are available.

Percutaneous Tricuspid Valve Annuloplasty Devices

The first group comprises percutaneous tricuspid valve annuloplasty devices, based either on transcatheter suture or ring implantation techniques.

Trialign™

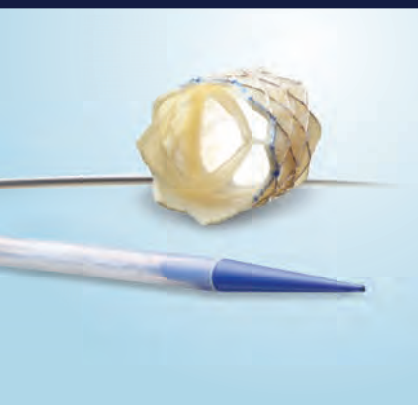
The Trialign™ device (Mitralign Inc.,

Tewksbury, MA, USA) is a transjugular suture-based tricuspid valve annuloplasty system which aims to reduce tricuspid annular diameter through tissue plication. During the Trialign procedure a pair of polyester pledgets is delivered across the tricuspid annulus from the ventricular to the atrial side in proximity to the anteroposterior and septoposterior commissure, cinched by a polyester suture to obliterate the posterior tricuspid leaflet and, finally, locked on the atrial side. Hence, from a mechanistic point of view, this approach replicates the surgical Kay procedure. The results of the SCOUT (Percutaneous Tricuspid Valve Annuloplasty System [PTVAS] for Symptomatic Chronic Functional Tricuspid Regurgitation) trial suggest that TR reduction by the Trialign device translates into improvements in NYHA functional class, Minnesota Living with Heart Failure Questionnaire score and six-minute walking distance in the intention-to-treat cohort¹⁴. In one patient, an intraprocedural ST-elevation myocardial infarction occurred due to tenting of the distal right coronary artery in the region of the plication with significant narrowing. Pledget detachment from the annulus was evident in 3/15 patients on follow-up after 30 days. No major adverse events were reported.

TriCinch™

The TriCinch™ system (4Tech Cardio, Galway, Ireland) aims to reduce the septolateral tricuspid annular diameter by implanting a nitinol coil anchor in the anteroposterior tricuspid annulus and applying tension on the annulus via a Dacron band fixed to a self-expanding nitinol stent in the inferior vena cava. Unpublished data from the PREVENT (Percutaneous

RIGHT CHOICE.



Melody™
Transcatheter Pulmonary
Valve (TPV) System



Not intended to constitute medical advice or in any way replace the independent medical judgment of a trained and licensed physician with respect to any patient needs or circumstances. Melody TPV is not suitable for all patients and ease of use, outcomes, and performance may vary. See the Instructions for Use for indications, contraindications, precautions, warnings, and adverse events.

Restoring lives for

11

years and counting.

The only transcatheter pulmonary valve specifically designed for RVOT conduits and bioprosthetic valves. The longest studied, with the largest body of clinical evidence at 7 years post-implant.* Over 11 years of implants, more than 12,000 patients' lives have been changed.

**Melody TPV — The Right Choice
for Your Patients**

*Melody Transcatheter Pulmonary Valve Study:
Post Approval Study of the Original IDE Cohort.
©2018 Medtronic. All rights reserved.
UC201809495 EN 02/2018

Medtronic
Further, Together

Melody™ Transcatheter Pulmonary Valve, Ensemble™ II Transcatheter Valve Delivery System

Important Labeling Information for the United States

Indications: The Melody TPV is indicated for use in the management of pediatric and adult patients who have a clinical indication for intervention on a dysfunctional right ventricular outflow tract (RVOT) conduit or surgical bioprosthetic pulmonary valve that has \geq moderate regurgitation, and/or a mean RVOT gradient \geq 35 mm Hg.

Contraindications: None known.

Warnings/Precautions/Side Effects:

- **DO NOT implant in the aortic or mitral position. Pre-clinical bench testing of the Melody valve suggests that valve function and durability will be extremely limited when used in these locations.**
- DO NOT use if patient's anatomy precludes introduction of the valve, if the venous anatomy cannot accommodate a 22 Fr size introducer, or if there is significant obstruction of the central veins.
- DO NOT use if there are clinical or biological signs of infection including active endocarditis. Standard medical and surgical care should be strongly considered in these circumstances.
- Assessment of the coronary artery anatomy for the risk of coronary artery compression should be performed in all patients prior to deployment of the TPV.
- To minimize the risk of conduit rupture, do not use a balloon with a diameter greater than 110% of the nominal diameter (original implant size) of the conduit for pre-dilation of the intended site of deployment, or for deployment of the TPV.
- The potential for stent fracture should be considered in all patients who undergo TPV placement. Radiographic assessment of the stent with chest radiography or fluoroscopy should be included in the routine postoperative evaluation of patients who receive a TPV.
- If a stent fracture is detected, continued monitoring of the stent should be performed in conjunction with clinically appropriate hemodynamic assessment. In patients with stent fracture and significant associated RVOT obstruction or regurgitation, reintervention should be considered in accordance with usual clinical practice.

Potential procedural complications that may result from implantation of the Melody device include the following: rupture of the RVOT conduit, compression of a coronary artery, perforation of a major blood vessel, embolization or migration of the device, perforation of a heart chamber, arrhythmias, allergic reaction to contrast media, cerebrovascular events (TIA, CVA), infection/sepsis, fever, hematoma, radiation-induced erythema, blistering, or peeling of skin, pain, swelling, or bruising at the catheterization site.

Potential device-related adverse events that may occur following device implantation include the following: stent fracture, stent fracture resulting in recurrent obstruction, endocarditis, embolization or migration of the device, valvular dysfunction (stenosis or regurgitation), paravalvular leak, valvular thrombosis, pulmonary thromboembolism, hemolysis.

"The term "stent fracture" refers to the fracturing of the Melody TPV. However, in subjects with multiple stents in the RVOT it is difficult to definitively attribute stent fractures to the Melody frame versus another stent.

For additional information, please refer to the Instructions for Use provided with the product or available on <http://manuals.medtronic.com>.

CAUTION: Federal law (USA) restricts this device to sale by or on the order of a physician.

Important Labeling Information for Geographies Outside of the United States

Indications: The Melody™ TPV is indicated for use in patients with the following clinical conditions:

- Patients with regurgitant prosthetic right ventricular outflow tract (RVOT) conduits or bioprostheses with a clinical indication for invasive or surgical intervention, OR
- Patients with stenotic prosthetic RVOT conduits or bioprostheses where the risk of worsening regurgitation is a relative contraindication to balloon dilatation or stenting

Contraindications:

- Venous anatomy unable to accommodate a 22 Fr size introducer sheath
- Implantation of the TPV in the left heart
- RVOT unfavorable for good stent anchorage
- Severe RVOT obstruction, which cannot be dilated by balloon
- Obstruction of the central veins
- Clinical or biological signs of infection
- Active endocarditis
- Known allergy to aspirin or heparin
- Pregnancy

Potential Complications/Adverse Events: Potential procedural complications that may result from implantation of the Melody device include the following: rupture of the RVOT conduit, compression of a coronary artery, perforation of a major blood vessel, embolization or migration of the device, perforation of a heart chamber, arrhythmias, allergic reaction to contrast media, cerebrovascular events (TIA, CVA), infection/sepsis, fever, hematoma, radiation-induced erythema, pain, swelling or bruising at the catheterization site.

Potential device-related adverse events that may occur following device implantation include the following: stent fracture, stent fracture resulting in recurrent obstruction, endocarditis, embolization or migration of the device, valvular dysfunction (stenosis or regurgitation), paravalvular leak, valvular thrombosis, pulmonary thromboembolism, hemolysis.

"The term "stent fracture" refers to the fracturing of the Melody TPV. However, in subjects with multiple stents in the RVOT it is difficult to definitively attribute stent fractures to the Melody frame versus another stent.

For additional information, please refer to the Instructions for Use provided with the product or available on <http://manuals.medtronic.com>.

The Melody Transcatheter Pulmonary Valve and Ensemble II Transcatheter Valve Delivery System has received CE Mark approval and is available for distribution in Europe.

medtronic.com

710 Medtronic Parkway
Minneapolis, MN 55432-5604
USA
Tel: (763) 514-4000
Fax: (763) 514-4879
Toll-free: (800) 328-2518

LifeLine
CardioVascular Technical Support
Tel: (877) 526-7890
Tel: (763) 526-7890
Fax: (763) 526-7888
rs.cstechsupport@medtronic.com

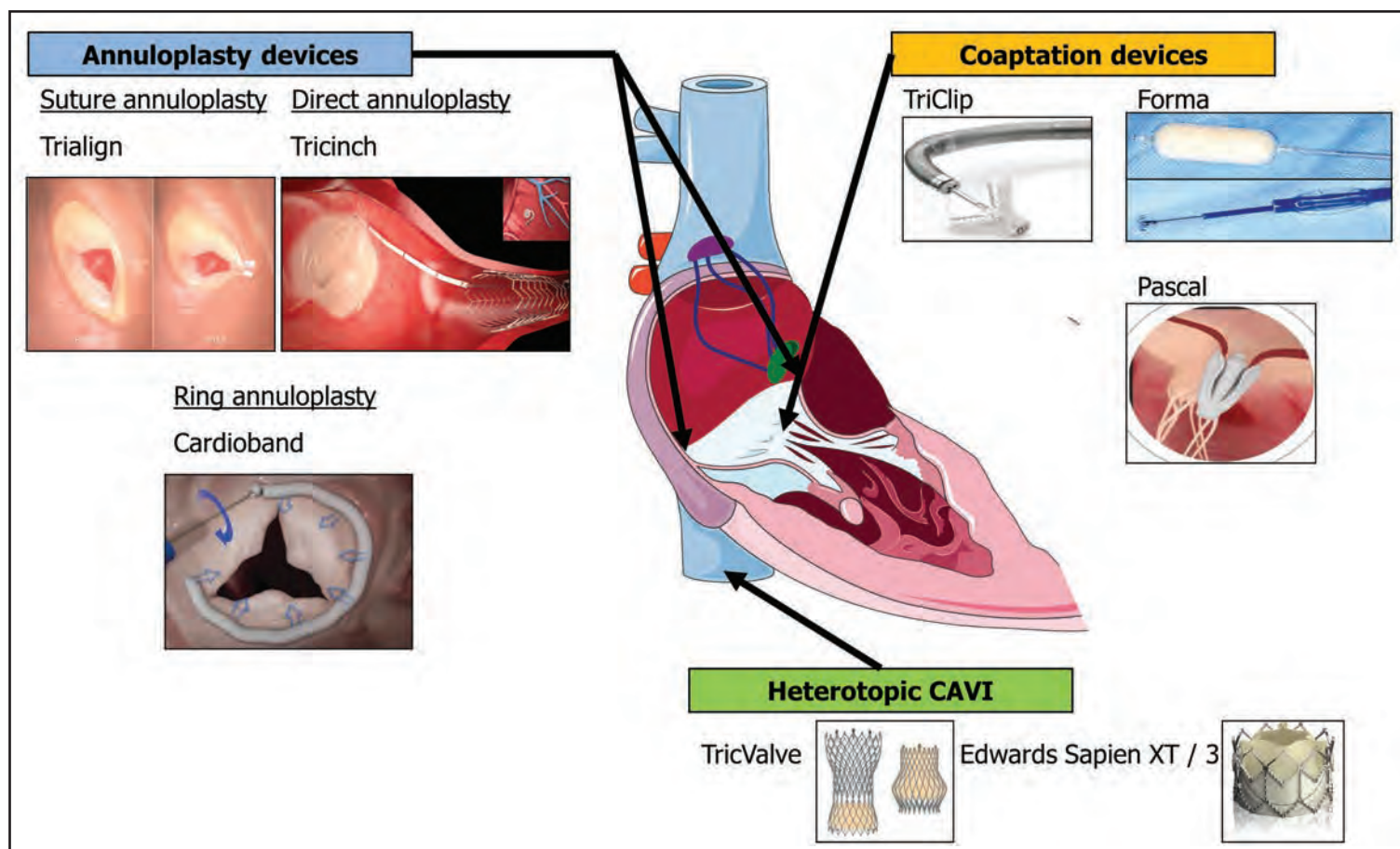


Figure 3. Transcatheter techniques targeting functional TR. Transcatheter devices in early clinical testing can be grouped according to their mechanism of action into annuloplasty devices, coaptation devices and heterotopic caval valve implantation.

Treatment of Tricuspid Valve Regurgitation with the TriCinch System) trial suggested an intraprocedural technical success rate of 81% in 24 patients with acute TR reduction by at least one grade in 94% of patients. Notably, late annular anchor detachment occurred in 23% of patients and an alternative coil anchoring system to improve annular fixation has been developed¹⁵.

Cardioband™ Tricuspid Valve Reconstruction System

The Cardioband implant (Edwards Lifesciences, Irvine, CA, USA) is composed of an adjustable fabric band with up to 17 anchors for annular fixation and was initially developed for patients with functional mitral regurgitation. The Cardioband tricuspid reconstruction system aims to reduce TR via annular reduction and is advanced into the right atrium via transfemoral access. The anchors are deployed on the beating heart along the anterior and posterior portion of the tricuspid annulus. At the end of the procedure, the Cardioband is contracted to reduce the tricuspid annular circumference. The TRI-REPAIR trial examined safety, efficacy and early functional benefits of TR treatment with the Cardioband tricuspid system¹⁵.

Percutaneous Tricuspid Valve Coaptation Devices

The second group currently includes three devices designed to improve leaflet coaptation in functional TR (Figure 3).

TriClip

According to recent registry data, the off-label transfer of the MitraClip® technique (Abbott Vascular, Santa Clara, CA, USA) to the tricuspid valve is so far the most common technique applied for interventional TR

treatment¹³. In the largest analysis published thus far, tricuspid valve edge-to-edge repair, carried out either in isolation or in combination with mitral valve edge-to-edge repair, led to an improvement in NYHA functional class in 76% of patients and a 29% increase in six-minute walk test distance¹². In addition, successful TriClip implantation was associated with reduced mortality and less readmission for heart failure. A small coaptation gap size of TR and a central or antero-septal location of the TR jet on echocardiography independently predicted procedural success of TriClip implantation¹². Notably, in patients with both significant mitral and tricuspid regurgitation at high surgical risk, combined transcatheter mitral plus tricuspid valve edge-to-edge repair using the MitraClip technique was associated with superior functional improvement (in terms of NYHA class, NT-proBNP levels and six-minute walk test distance) and fewer hospitalisations for heart failure as compared to isolated mitral valve edge-to-edge repair¹⁶. Whether application of the novel MitraClip XTR system with longer clip arms and longer grippers with two additional rows of frictional elements will improve the technical success rate in patients with functional TR is the subject of current research.

FORMA

The FORMA repair system (Edwards Lifesciences, Irvine, CA, USA) aims to reduce malcoaptation of the tricuspid leaflets by placing a balloon spacer through the central coaptation line, which reduces the regurgitant orifice area. The device is advanced via the left subclavian or axillary vein. The spacer is stabilized by a rail anchored at the right ventricular apex. Three different balloon sizes (12, 15 and 18 mm) have been implanted. Early results of 18 patients treated on a compassionate use basis yielded encouraging results with successful device implantation in 16 patients and reduction of TR severity in all

but one patient with a successfully implanted device¹⁷. Moreover, functional improvement on follow-up was evident in patients with successful implantation of the FORMA system. One patient was diagnosed with thrombosis of a spacer that occurred during hospitalization for treatment of pneumonia four months post procedure. The patient had non-therapeutic international normalized ratios on warfarin; following antibiotic treatment and resumption of adequate anticoagulation, the thrombus resolved within two months. Recently, the 30-day outcomes of 29 patients treated with the FORMA device within the US Early Feasibility Study were reported. Intraprocedural perforation of the right ventricle occurred in two patients and nine patients had at least one adverse event after 30 days of follow-up, including death, vascular injury, major or life-threatening bleeding and device-related surgery because of device perforation, migration or infection. Technical improvements are currently underway to minimize the risk of such adverse events in upcoming trials¹⁵.

PASCAL

The PASCAL system (Edwards Lifesciences, Irvine, CA, USA) has undergone first-in-human, compassionate use experience in 23 patients with severe mitral regurgitation¹⁸. Recently, the device was successfully implanted in a patient with severe functional TR for the first time. The novel PASCAL system incorporates a spacer to fill the regurgitant jet area, paddles designed to avoid stress concentration on native leaflets, and clasps which allow for independent leaflet capture. Hence, the PASCAL device in a way integrates the mode of action of the FORMA and the TriClip devices.

Heterotopic Caval Valve Implantation (CAVI)

The third group comprises techniques for heterotopic caval valve implantation, where either two dedicated self-expanding bioprosthetic valves (TricValve; P&F Products & Features Vertriebs GmbH, Vienna, Austria,) or balloon-expandable valves used to treat aortic stenosis (29 mm Edwards SAPIEN XT or SAPIEN 3; Edwards Lifesciences, Irvine, CA, USA) are placed in the inferior and superior vena cava [19]. The use of balloon-expandable valves requires prior implantation of a self-expanding stent in the inferior (and occasionally superior) vena cava to prepare a landing zone, given the large diameter of the vena cava and the hepatic vein confluence. The technique was recently tested in an excess-risk cohort and appeared safe and feasible with a high procedural success rate. Substantial in-hospital and 30 day-mortality rates were attributed to severe and non-device-related comorbidities in these patients¹⁹.

Comparison Between Treatment Modalities for Functional TR

A retrospective analysis of patients with isolated TR suggests that severe TR is a serious disease characterized over time by a cumulative high rate of complications. Only 31% of patients were free from cardiac events (i.e., development of heart failure, atrial fibrillation, need for surgery, or death) at 15 years after diagnosis. In these patients, surgical repair of the tricuspid valve was feasible, with low operative mortality and marked symptomatic improvement in 88% of patients, indicating that surgical is superior to medical treatment in patients with isolated severe TR²⁰. Prospective data comparing different treatment modalities are lacking. However, with the advent of transcatheter therapies targeting TR in patients at high surgical risk, the question may arise as to whether these techniques are indeed superior to optimal medical therapy alone.

Conclusion

Moderate-to-severe functional TR is a common problem in everyday practice associated with a considerable symptomatic burden and poor prognosis. Medical treatment options for TR are limited.

Surgical tricuspid valve repair should be carried out in a timely manner according to recommendations given in current guidelines. A variety of transcatheter devices is currently in clinical testing to provide alternative treatment options for patients deemed at high risk for surgical tricuspid valve repair. Despite promising early data on safety and efficacy, further studies are needed for most of the devices targeting functional TR to validate the long-term effect on functional status and hard clinical endpoints. Finally, the question as to whether transcatheter TR treatment in elderly patients at high surgical risk is superior to medical treatment alone remains to be answered.

References

1. Badano LP, Muraru D, Enriquez-Sarano M. Assessment of functional tricuspid regurgitation. *Eur Heart J*. 2013;34:1875-85.
2. Taramasso M, Pozzoli A, Guidotti A, Nietlispach F, Inderbitzin DT, Benussi S, Alfieri O, Maisano F. Percutaneous tricuspid valve therapies: the new frontier. *Eur Heart J*. 2017;38:639-47.
3. Schueler R, Öztürk C, Sinning JM, Werner N, Welz A, Hammerstingl C, Nickenig G. Impact of baseline tricuspid regurgitation on long-term clinical outcomes and survival after interventional edge-to-edge repair for mitral regurgitation. *Clin Res Cardiol*. 2017;106:350-8.
4. Sathananthan J, Murdoch DJ, Lindman BR, Zajarias A, Jaber WA, Cremer P, Wood D, Moss R, Cheung A, Ye J, Hahn RT, Crowley A, Leon MB, Mack MJ, Webb JG. Implications of Concomitant Tricuspid Regurgitation in Patients Undergoing Transcatheter Aortic Valve Replacement for Degenerated Surgical Aortic Bioprosthesis: Insights From the PARTNER 2 Aortic Valve-in-Valve Registry. *JACC Cardiovasc Interv*. 2018;11:1154-60.
5. Ponikowski P, Voors AA, Anker SD, Bueno H, Cleland JGF, Coats AJS, Falk V, González-Juanatey JR, Harjola VP, Jankowska EA, Jessup M, Linde C, Nihoyannopoulos P, Parissis JT, Pieske B, Riley JP, Rosano GMC, Ruilope LM, Ruschitzka F, Rutten FH, van der Meer P; ESC Scientific Document Group. 2016 ESC Guidelines for the diagnosis and treatment of acute and chronic heart failure: The Task Force for the diagnosis and treatment of acute and chronic heart failure of the European Society of Cardiology (ESC) Developed with the special contribution of the Heart Failure Association (HFA) of the ESC. *Eur Heart J*. 2016;37:2129-200.
6. Baumgartner H, Falk V, Bax JJ, De Bonis M, Hamm C, Holm PJ, Iung B, Lancellotti P, Lansac E, Rodriguez Muñoz D, Rosenhek R, Sjögren J, Tornos Mas P, Vahanian A, Walther T, Wendler O, Windecker S, Zamorano JL; ESC Scientific Document Group. 2017 ESC/EACTS Guidelines for the management of valvular heart disease. *Eur Heart J*. 2017;38:2739-91.
7. Pagnesi M, Montalto C, Mangieri A, Agricola E, Puri R, Chiarito M, Ancona MB, Regazzoli D, Testa L, De Bonis M, Moat NE, Rodés-Cabau J, Colombo A, Latib A. Tricuspid annuloplasty versus a conservative approach in patients with functional tricuspid regurgitation undergoing left-sided heart valve surgery: A study-level meta-analysis. *Int J Cardiol*. 2017;240:138-44.
8. Antunes MJ, Rodríguez-Palomares J, Prendergast B, De Bonis M, Rosenhek R, Al-Attar N, Barili F, Casselman F, Folliguet T, Iung B, Lancellotti P, Muneretto C, Obadia JF, Pierard L, Suwalski P, Zamorano P; ESC Working Groups of Cardiovascular Surgery and Valvular Heart Disease. Management of tricuspid valve regurgitation: Position statement of the European Society of Cardiology Working Groups of Cardiovascular Surgery and Valvular Heart Disease. *Eur J Cardiothorac Surg*. 2017;52:1022-30.
9. Shinn SH, Schaff HV. Evidence-based surgical management of acquired tricuspid valve disease. *Nat Rev Cardiol*. 2013;10:190-203.
10. Pfannmüller B, Doenst T, Eberhardt K, Seeburger J, Borger MA, Mohr FW. Increased risk of dehiscence after tricuspid valve repair with rigid annuloplasty rings. *J Thorac Cardiovasc Surg*. 2012;143:1050-5.
11. Seeburger J, Borger MA, Passage J, Misfeld M, Holzhey D, Noack T, Sauer M, Ender J, Mohr FW. Minimally invasive isolated tricuspid valve surgery. *J Heart Valve Dis*. 2010;19:189-92.

12. Besler C, Orban M, Rommel KP, Braun D, Patel M, Hagl C, Borger M, Nabauer M, Massberg S, Thiele H, Hausleiter J, Lurz P. Predictors of Procedural and Clinical Outcomes in Patients With Symptomatic Tricuspid Regurgitation Undergoing Transcatheter Edge-to-Edge Repair. *JACC Cardiovasc Interv.* 2018;11:1119-28.
13. Taramasso M, Hahn RT, Alessandrini H, Latib A, Attinger-Toller A, Braun D, Brochet E, Connelly KA, Denti P, Deuschl F, Englmaier A, Fam N, Frerker C, Hausleiter J, Juliard JM, Kaple R, Kreidel F, Kuck KH, Kuwata S, Ancona M, Malasa M, Nazif T, Nickenig G, Nietlispach F, Pozzoli A, Schäfer U, Schofer J, Schueler R, Tang G, Vahanian A, Webb JG, Yzeiraj E, Maisano F, Leon MB. The International Multicenter TriValve Registry: Which Patients Are Undergoing Transcatheter Tricuspid Repair? *JACC Cardiovasc Interv.* 2017;10:1982-90.
14. Hahn RT, Meduri CU, Davidson CJ, Lim S, Nazif TM, Ricciardi MJ, Rajagopal V, Ailawadi G, Vannan MA, Thomas JD, Fowler D, Rich S, Martin R, Ong G, Groothuis A, Kodali S. Early Feasibility Study of a Transcatheter Tricuspid Valve Annuloplasty: SCOUT Trial 30-Day Results. *J Am Coll Cardiol.* 2017;69:1795-1806.
15. Asmarats L, Puri R, Latib A, Navia JL, Rodés-Cabau J. Transcatheter Tricuspid Valve Interventions: Landscape, Challenges, and Future Directions. *J Am Coll Cardiol.* 2018;71:2935-56.
16. Besler C, Blazek S, Rommel KP, Noack T, von Roeder M, Luecke C, Seeburger J, Ender J, Borger MA, Linke A, Gutberlet M, Thiele H, Lurz P. Combined Mitral and Tricuspid Versus Isolated Mitral Valve Transcatheter Edge-to-Edge Repair in Patients With Symptomatic Valve Regurgitation at High Surgical Risk. *JACC Cardiovasc Interv.* 2018;11:1142-51.
17. Perlman G, Praz F, Puri R, Ofek H, Ye J, Philippon F, Carrel T, Pibarot P, Attinger A, Htun NM, Dvir D, Moss R, Campelo-Parada F, Bédard E, Reineke D, Moschovitis A, Lauck S, Blanke P, Leipsic J, Windecker S, Rodés-Cabau J, Webb J. Transcatheter Tricuspid Valve Repair With a New Transcatheter Coaptation System for the Treatment of Severe Tricuspid Regurgitation: 1-Year Clinical and Echocardiographic Results. *JACC Cardiovasc Interv.* 2017;10:1994-2003.
18. Praz F, Spargias K, Chrissoheris M, Büllsfeld L, Nickenig G, Deuschl F, Schueler R, Fam NP, Moss R, Makar M, Boone R, Edwards J, Moschovitis A, Kar S, Webb J, Schäfer U, Feldman T, Windecker S. Compassionate use of the PASCAL transcatheter mitral valve repair system for patients with severe mitral regurgitation: a multicentre, prospective, observational, first-in-man study. *Lancet.* 2017;390:773-80.
19. Lauten A, Figulla HR, Unbehaun A, Fam N, Schofer J, Doenst T, Hausleiter J, Franz M, Jung C, Dreger H, Leistner D, Alushi B, Stundl A, Landmesser U, Falk V, Stangl K, Laule M. Interventional Treatment of Severe Tricuspid Regurgitation: Early Clinical Experience in a Multicenter, Observational, First-in-Man Study. *Circ Cardiovasc Interv.* 2018;11:e006061.
20. Messika-Zeitoun D, Thomson H, Bellamy M, Scott C, Tribouilloy C, Dearani J, Tajik AJ, Schaff H, Enriquez-Sarano M. Medical and surgical outcome of tricuspid regurgitation caused by flail leaflets. *J Thorac Cardiovasc Surg.* 2004;128:296-302.

Originally published in *European Society of Cardiology's E-Journal of Cardiology Practice* - Vol. 16, N° 31 - 28 Nov. 2018

www.escardio.org/Journals/E-Journal-of-Cardiology-Practice/Volume-16/Treatment-options-for-severe-functional-tricuspid-regurgitation-indications-techniques-and-current-challenges



Christian Besler, MD

Corresponding Author
*Department of Cardiology
 Heart Center Leipzig
 University Hospital
 Leipzig, Germany
 ChristianBesler@gmx.de*



Joerg Seeburger, MD

*Department of Cardiac Surgery
 Heart Center Leipzig
 University Hospital
 Leipzig, Germany*



Holger Thiele, MD

*Department of Cardiology
 Heart Center Leipzig
 University Hospital
 Leipzig, Germany*



Philipp Lurz, MD, PhD

*Department of Cardiology
 Heart Center Leipzig
 University Hospital
 Leipzig, Germany
 +49-341-865-1428
 Philipp.Lurz@gmx.de*

Transition of Care for Congenital Heart Patients: Challenges, Opportunities, and Pathways for Providers

By Wayne J. Franklin, MD

It wasn't long ago when Congenital Heart Defects (CHDs) were a critical condition for the vast majority of pediatric patients. In the 1940's, the survival rate for highly complex conditions was lower than 10%. However, breakthroughs in the detection and treatment of CHD have reversed the prognosis for children born with severe defects. Now, where treatment is available, more than 90% of infants born with CHD survive into adulthood.

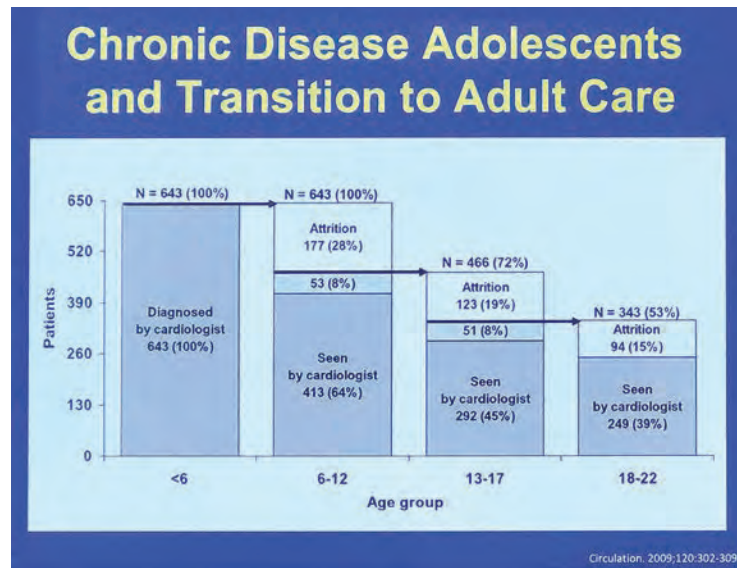


Figure 1. The graph shows that as children with chronic disease grow up, they are seen less frequently by a pediatric cardiologist.

In many ways, these advancements underscore the tremendous potential of modern medicine. Congenital Heart Disease (CHD) often can be diagnosed in utero through fetal echocardiology, allowing clinicians to assess the presence and complexity of heart defects prior to birth and create an intervention plan. In cases like tachycardia, medication can be delivered in utero. Post birth, advances in neonatal heart surgery have improved outcomes for infants born with CHD, giving them a shot at a normal lifespan. Even in premature infants weighing fewer than five pounds, surgical options to repair heart problems are often possible.

This transformation is encouraging for patients and their doctors, but it's also the root of a trend that presents new challenges for health systems in providing ongoing care for patients living with Adult Congenital Heart Disease (ACHD).

For example, a shortage of cardiologists trained to treat ACHD means that many patients must travel far for the care they need. Indeed, approximately two-thirds of people living with moderate or complex CHD are over 18 years old. This means an estimated 1.3 million adults in America are living with the condition. Yet, few cardiologists possess the specialized knowledge and experience to treat this growing group of patients. This is especially concerning when you factor in the unique health challenges of adult patients with CHD, including the risks associated with pregnancy, exercise and vulnerability to critical heart episodes.

In response to the scarcity of providers serving this new and expanding group of patients, the American Congenital Heart Association (ACHA), the American College of Cardiology (ACC), and the American Heart Association (AHA) have launched a program to accredit hospitals in the treatment of ACHD. The nine-month process evaluates hospitals on 43 criteria, each tied to precise metrics, and includes a site visit to assess compliance with best practices in the field.

Additionally, the American Board of Internal Medicine (ABIM) and the American Board of Pediatrics (ABP) have created a certification exam for doctors seeking to treat patients with ACHD.

Approximately 308 doctors have passed this exam, and more than 20 hospitals have become ACHD-certified. While these initiatives show enormous potential, the relatively small number of certified programs and doctors, when compared to the demand among ACHD patients, continues to be a challenge for health systems.

Further, the challenges do not end once a cardiologist earns certification in treating ACHD. Increasingly, hospitals are noting and addressing difficulties in transitional care for pediatric patients reaching adulthood – in CHD and across all disease groups.

Usually, young adulthood is the time of life when patients are shifting their routines, moving out of the family home, attending college, and even aging out of their parents' health insurance coverage. Lifestyle changes including diet, alcohol consumption, and physical activity outside of a supervised environment are also common.

Studies also indicate that patients often experience stress, frustration, feelings of isolation and other psychological effects as they confront the challenges of transitioning to adulthood while balancing a chronic illness.

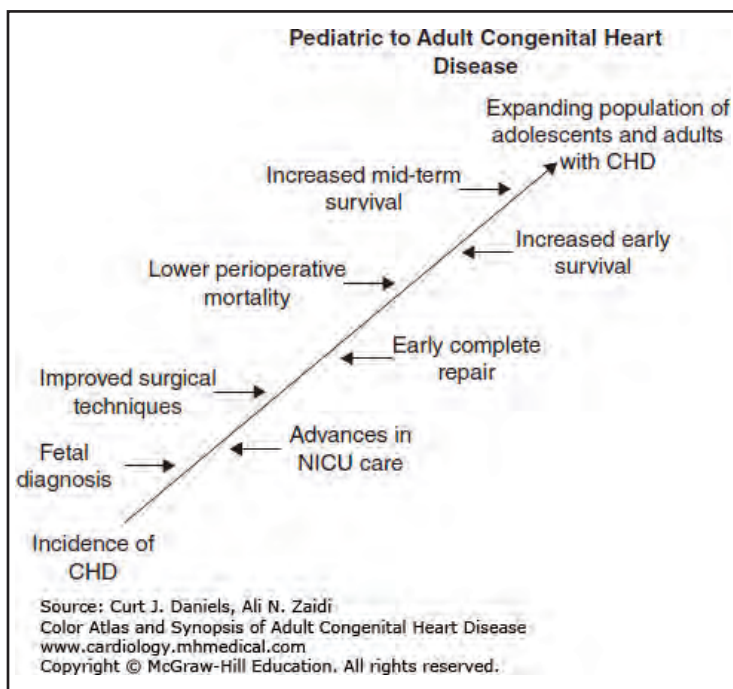


Figure 2. The graph shows reasons why there is an increasing number of adolescents and adults with CHD.

Chief of Pediatric Cardiology

Orlando, Florida

The Walt Disney Pavilion at AdventHealth for Children (AHFC) - formerly Florida Hospital for Children - and AdventHealth Medical Group (AHMG) - formerly Florida Hospital Medical Group - are looking for a dynamic and experienced Chief in Pediatric Cardiology to lead our growing program. The group is open to both noninvasive and interventional cardiology backgrounds. The new leader will also have experience with both inpatient and outpatient settings, including outreach strategies. The position will involve clinical responsibilities with protected administrative time.

The pediatric cardiology division is part of a full-service program including six cardiologists (with plans to continue to grow), two world class cardiothoracic surgeons, a robust intensive care group, top cardiac anesthesia and surgical results rivaling any program in the country. Our state of the art hybrid catheterization laboratory see over 150 diagnostic/interventional procedures and over 125 electrophysiology procedures annually. We also performed over 200 surgeries in 2018. There is a robust adult congenital cardiology population and we have a board certified adult congenital cardiologist in the group. The group has seven outpatient locations in six counties covering a population of 2.75 million people.

Working with an expanding and committed children's hospital, a strong employed physician multispecialty group, a family-centered practice atmosphere, and a competitive benefits/compensation package are just a few of the many reasons why this is an excellent career opportunity to consider.

Requirements of the position include:

- Experience with inpatient and outpatient settings
- At least 7-10 years of experience post fellowship
- Board certification in Pediatric Cardiology through ABP
- Prior group leadership experience is preferred

Our Walt Disney Pavilion at AdventHealth for Children is a full service, tertiary children's hospital with over 200 dedicated pediatric beds, more than 30 peds ICU beds with a dedicated peds CICU, a 102 bed NICU, 17 bed pediatric emergency department and statewide pediatric network and transport system. We started our comprehensive pediatric open heart program in 2012 and have a strong track record of positive outcomes. We also have several key destination programs including our level IV Epilepsy program, and we increased Orlando area NICU beds to 150 total in 2017. Our unparalleled network consists of 27 hospitals across the state with one children's hospital at the center totals over 20,000 births and several extremely successful pediatric subspecialty programs including outreach clinics. These 27 hospitals refer patients for tertiary and quaternary services to our main location near downtown Orlando. Our newest program has brought pediatric liver transplant services to Central Florida.

For more information or to submit your CV directly:

Jason Junker, Director, Provider Recruitment

phone: (407) 200-2538

Jason.Junker@AdventHealth.com



Information for Transition Medicine

Preliminary Strategies

Increasing Awareness and Commitment

- Increase one's personal awareness of transition
- Educate colleagues in order to secure their commitment and support
- Consult with relevant external resources
- Secure commitment from administration
- Identify resources within one's health care team
 - Personnel
 - Time and space
 - Finance
 - Other subspecialists
 - Media

Transition Projects

Specific Components of a Transition Plan

- Develop a database
- Develop a written transition plan
- Make a habit of speaking to young people on their own
- Display a public commitment to transition
- Establish education as a priority
 - Develop an educational curriculum
 - Create an educational checklist
- Establish transition clinic
- Organize transition events
- Provide a portable medical summary
- Provide a coordinated and celebrated transfer of care
- Consider joint pediatric and adult congenital heart disease provider meetings
- Evaluate transition strategies

Saidi AB. Cong Hear Dis. 2009

Taken together, all of these factors can be barriers to effectively managing ACHD. In response to these challenges, hospitals are taking a highly proactive stance in providing transitional care to patients with ACHD and other complex conditions.

At Phoenix Children's Hospital, we develop a long-term, phased transition plan for each of our CHD patients that includes milestone dates – like being old enough to sign their own consent forms – and a litany of other important details.

In order to encourage patient participation in their own health, adolescents are engaged early in the transition process. By the time they're ready to transition to adult care, they can articulate the details of their condition and manage their own medications. They know who to contact in case of emergency, can identify any warning signs, understand any precautions related to diet, exercise and reproductive health, and are ready to advocate for their own healthcare.

This process is often simplified for our patients here at Phoenix Children's. Like a handful of other children's hospitals nationwide, we offer expertise in treating ACHD. For patients with the most complex cases, our team serves as a safeguard and ensures access to the best possible care.

However, amid a shortage of ACHD providers, we're keenly aware of the need for a team-based approach in caring for this highly complex patient population. To begin addressing patients' needs here in Phoenix, we host regular trainings to educate primary care providers, adult cardiologists and adult pulmonologists who provide general care to these patients and identify when a patient should see an ACHD specialist. At the center of this model is the primary care physician, a role that will, for many adult patients, be a critical referral source organizing ongoing care throughout the patient's lifetime.

While we celebrate the medical breakthroughs that have given ACHD patients a chance at a normal life, we have much work to do to ensure their long-term health and safety. The percentage of adults living with the disease continues to increase relative to the overall CHD patient population – and the number of qualified providers must increase to meet the current and future demand. The increasing focus on transitional care across all disease groups, along with the ongoing evolution of healthcare systems to meet the needs of adolescents and adults living with ACHD, give us reason to be hopeful.

CHD Prevalence is Increasing

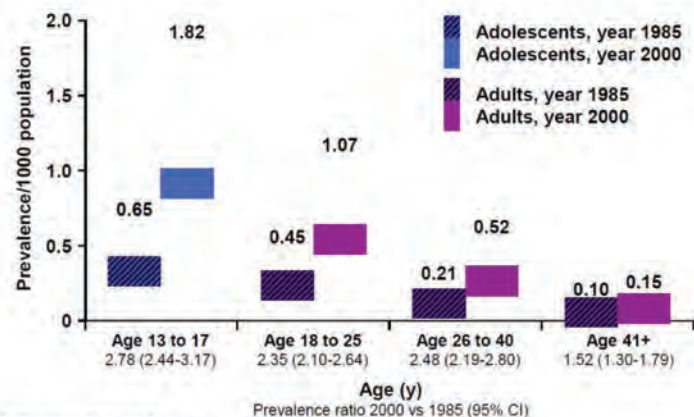


Figure 4. The graph shows that the number of teenagers and young adults is increasing.



Wayne J. Franklin, MD

Co-Director of Phoenix Children's Heart Center

Director of the Adult Congenital Heart Disease Program

Chair of Adult Medicine

Phoenix Children's Hospital

Phoenix, AZ, USA

wfranklin@phoenixchildrens.com

MaineHealth Physician Recruitment Center

PEDIATRIC CARDIOLOGIST

Congenital Heart has been the premier Congenital Cardiology Practice in the state of Maine for over 50 years. We are excited to announce that Congenital Heart is partnering with Maine Medical Partners and MaineHealth. This partnership will form the new Division of Pediatric Cardiology and Congenital Heart Care at Maine Medical Center. Commensurate with this partnership is the opportunity to expand with the addition of three Pediatric Cardiologists:

- 1) **BC Pediatric Electrophysiologist** with expertise in the management of pediatric and adult-congenital electrophysiology. The applicant should be technically proficient in radiofrequency/cryoablation, pacemaker/AICD insertion and management, and ventricular tachycardia ablation. The applicant will work closely with a large group of busy adult electrophysiologists but function as the director of the Pediatric and Adult-Congenital EP program.
- 2) **BC non-invasive Pediatric Cardiologist** with at least 6-8 years of clinical experience in a busy clinical/academic center with expertise and advanced training in echocardiography (fetal, TTE and TEE) with the ability to provide imaging and related consultation in the operating room and catheterization laboratory. This individual should possess leadership skills and desire to advance into leadership positions within the division. A research interest is encouraged with opportunities for collaboration with established research institutes like the Maine Medical Cardiovascular Research Institute (MMCRI).
- 3) **BE/BC non-invasive Pediatric Cardiologist** with expertise and advanced training in echocardiography (fetal, TTE and TEE) with the ability to provide imaging and related consultation in the operating room and catheterization laboratory. The candidate would ideally have clinical interest and experience in the management of Heart Failure and Cardiomyopathy. A research interest is encouraged with opportunities for collaboration with established research institutes like the Maine Medical Cardiovascular Research Institute (MMCRI).

General Pediatric Cardiology call responsibilities will be shared with the other members of the division.

These candidates will join 4 other Pediatric Cardiologists, who have established the only comprehensive Congenital Heart program in the state of Maine. The program has recently hired an experienced surgeon to serve as the Director of Congenital Cardiac Surgery. Comprehensive catheter-based interventional services and state-of-the-art imaging are performed.

Inpatient responsibilities are at The Barbara Bush Children's Hospital, a 96-bed hospital within Maine Medical Center - the tertiary medical center for children serving the state of Maine and southern and eastern New Hampshire. The Children's Hospital medical staff represents all of the pediatric medical and surgical subspecialties that provide comprehensive services for children. Maine Medical Center (MMC) has a full complement of Residencies and Fellowships and functions as an integral part of Tufts University Medical School.

Situated on the Maine coast, Portland offers the best of urban sophistication combined with seaside charm. It receives tourists from around the world with nationally recognized restaurants, breweries, and hotels. The area has an active outdoor community providing four-season recreational opportunities such as skiing, hiking, sailing, and miles of beautiful beaches. Just two hours north of Boston, this is an exceptionally diverse and vibrant community.



For more information, please contact Gina Mallozzi, Physician Recruiter, at (207) 661-2092 or gmallozzi@mmc.org.

9th Annual Phoenix Fetal Cardiology Symposium Summary

By Chris Lindblade, MD

The 9th Annual Phoenix Fetal Cardiology Symposium has been touted as one of the best so far! Over 255 attendees comprised of pediatric cardiologists, maternal fetal medicine specialists, obstetricians, neonatologists, radiologists, geneticists, pathologists, cardiac sonographers, obstetrical sonographers, advanced practitioners, nurses, and trainees gathered in Phoenix, Arizona, November 2nd-6th, 2018. The conference attracted 43 international attendees from 13 different countries who attended in person and via livestream connection. It was a dynamic and memorable educational event. Here are a few highlights from the Symposium.

- Three pre-conference tracks were attended by over 100 people this year. The Essentials of Fetal Cardiac Screening Hands-On Scanning course paired attendees with physician and sonographer faculty to give everyone the opportunity to learn how to perform a fetal echo in a step-wise fashion based on standard guidelines. Beautiful cardiac specimens were presented during the Fetal and Neonatal Cardiac Pathologic Specimen and Echo Correlation alongside the fetal echo correlates. The Fetal Nurse Coordinator Collaborative attracted nearly 30 nurses from institutions across North America to learn about the psychosocial aspects of care, potential for collaborative projects under the umbrella of the Fetal Heart Society, and development of patient education materials.
- World experts in the field of fetal cardiology delivered top-notch lectures during the four-day General Session. Panel discussions and debates took place throughout the Session. We were honored to have Dr. Abraham Rudolph, one of the pillars in our field, speak on his research in Fetal Cardiovascular Physiology. Dr. William Evans delivered a most memorable keynote address on the History of the Maude Abbott Collection. Dr. Chris Lindblade hosted a newly created Fetal Echo Jeopardy session where the faculty panel showed off their knowledge and competitive spirit!
- The newly named Norman H. Silverman "The Case that Gave Me Chest Pain" Competition was a true

highlight of the course. All of the presenters did a fantastic job showing challenging fetal cardiology cases which sparked great open discussion amongst the faculty and attendees. Dr. Mika Saito, from The Hospital for Sick Children, won the coveted Nitroglycerin Award for her case presentation, "Arrhythm-a-palooza."

Oral and poster abstracts highlighting fetal cardiology research were presented with the best abstract oral presentation delivered by Dr. Hiba Mustafa on "Preterm Birth of Infants Prenatally Diagnosed with Congenital Heart Disease."

- The Fetal Heart Society held their annual membership meeting during the conference presenting current research projects and outlined how centers can get involved in multi-center research. For more information about the Fetal Heart Society membership and their projects, go to their website www.fetalheartsociety.org.
- Attendees also took advantage of evening activities which included a Welcome Reception and a tour of the Phoenix Children's Hospital Heart Center, 3-D Print Lab, and the CVICU.

Mark your calendars to attend the 10th Annual Phoenix Fetal Cardiology Symposium on November 7-11, 2019 at the Scottsdale Plaza Resort. There will be an emphasis on the maternal congenital cardiac care during pregnancy and the maternal-fetal environment this year. You don't want to miss this great opportunity to hear from leaders in the field.

We hope to see you there!

www.fetalcardio.com



PHOENIX CHILDREN'S
Hospital



Chris Lindblade, MD

*Symposium Program Chair
Director
Fetal Cardiology Program
Phoenix Children's Hospital
Phoenix, AZ, USA
clindblade@phoenixchildrens.com*

Medical News, Products & Information

Compiled and Reviewed by Kate Baldwin and Tony Carlson

A research study is currently being conducted entitled "Aortopulmonary Collaterals in Patients with Single Ventricle Circulation" under the direction of Dr. Joseph J. Vettukattil at Spectrum Health Helen DeVos Children's Hospital in Grand Rapids, MI, and Dr. Ziyad M. Hijazi at Sidra Heart Center in Doha, Qatar. The study involves filling out a one-time voluntary survey regarding your experience in occluding aortopulmonary collaterals (APC) in patients with single ventricle circulation. The impact of APCs on post-operative and long-term outcomes is debatable. Additionally, no guidelines are currently available on how to treat APCs. As such, practice varies among institutions and interventional cardiologists. Through this study we hope to learn about the different approaches for the treatment of APCs and possibly develop future studies to understand APC physiology and its impact on single ventricle circulation.

The survey can be found at:
www.j.mp/2SHmuWu

This survey is the only research procedure being performed for this study. Participation is completely voluntary, but your help is greatly appreciated as we work to gather the most valid data possible for this research study.

All information collected during the course of the study will be anonymous and kept confidential to the extent permitted by law. No personal or patient-protected health information is being collected as part of this study. Data collected for this study will be uploaded to a password protected, and secure website (REDCap hosted at Spectrum Health).

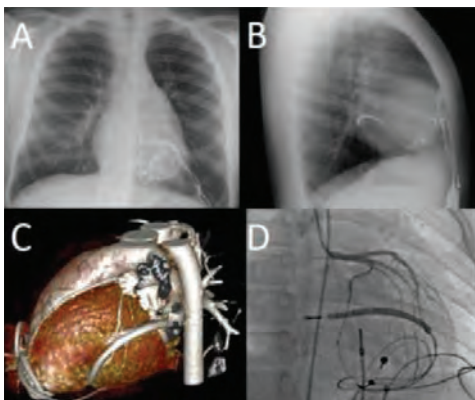
If you have any questions or concerns, please feel free to contact:
Dr. Joseph Vettukattil
616.267.2334
joseph.vettukattil@helendevoschildrens.org

You may also talk to the Spectrum Health Institutional Review Board at 616.486.2031 or irb@spectrumhealth.org if, 1) your questions, concerns, or complaints are

not being answered by the investigator or research team, 2) you have questions about your rights as a research participant, or, 3) you want to get information or provide input about this research.

The Danger of Coronary Artery Compression in Children is More Common Than We Think

Children fitted with epicardial pacemakers should be regularly screened to detect those at risk for coronary artery compression, recommend scientists in the journal HeartRhythm



Images of the different imaging techniques used to diagnose one of the patients who displayed symptoms. Chest x-ray in the posterior-anterior (A) and lateral (B) projections, showing the classic pattern of cardiac strangulation from epicardial leads, as the ICD lead courses leftward and posterior around the heart. Computed topography (C) shows the ICD lead constricting the left ventricle and obtuse marginal branch of the circumflex artery. Catheter angiography (D) shows loss of contrast within the obtuse marginal branch as it courses below the ICD lead. Credit: HeartRhythm

The incidence of coronary artery compression in children fitted with epicardial pacemakers may be slightly more common than previously believed, say noted cardiologists. After reviewing patient records at Boston Children's Hospital, they advocate for stricter monitoring to identify patients at risk and prevent complications. Their recommendations are published as a featured article in the



EP/Pacemaker Nurse

We are seeking a candidate to replace our retiring EP Nurse expert at Rady Children's Hospital San Diego.

Position includes:

- Pacemaker/device clinic and programming (320 active patients)
- Ambulatory monitoring surveillance
- Patient care coordination including young adult CHD patients
- Channelopathy and EP lab database management
- EP lab recording
- Nursing and fellow education
- Opportunities for research involvement

Travel to annual HRS meeting included.

Contact with letter of interest and CV:

James Perry, MD
jperry@rchsd.org
Matt Williams, MD
mwilliams@rchsd.org

journal, *HeartRhythm*, the official journal of the Heart Rhythm Society and the Cardiac Electrophysiology Society.

Children who require pacemakers or defibrillators often need to have wires placed on the outside of their heart due to their size or unique anatomy. In rare instances, these wires can place the child at risk for “cardiac strangulation,” which can lead to compression of the heart muscle and coronary arteries (the blood vessels that feed the heart) over time.

“Coronary artery compression is thought to be rare,” explained lead investigator Douglas Y. Mah, MD, Director of the Pacemaker and ICD Program in the Department of Cardiology, Boston Children’s Hospital, and Assistant Professor of Pediatrics, Harvard Medical School, Boston, MA, USA. “Its true incidence, however, may be higher than we believed due either to a lack of awareness or lack of reporting in the literature.”

The sudden death of a child with an epicardial pacemaker following coronary artery compression prompted investigators to enhance surveillance of all patients with epicardial pacing or defibrillation systems. They reviewed the records of all patients followed at Boston Children’s Hospital from 2000-2017 who had either active or abandoned epicardial wires that included coronary imaging, either by computed topography (CT) scan or catheter angiography through the vessels in the leg. Of 145 patients, eight (5.5%) exhibited some degree of coronary compression from their epicardial leads. Six of these patients displayed symptoms; in addition to the case of sudden death, there were three cases of chest pain and two cases of unexplained fatigue. As a result of the review, seven patients underwent surgical removal or repositioning of their epicardial leads.

This study helps provide a framework for monitoring patients with epicardial pacemakers or defibrillators and identifying those who may need revision or removal of their epicardial wires. Dr. Mah and colleagues compared three screening techniques. They recommend that pediatric patients with epicardial devices should get screening chest x-rays every few years to assess how their wires look in relation to their heart, as the positioning may change as the child grows. They found that chest x-ray had a high specificity and was a good screening tool, easy to perform,

inexpensive, and non-invasive. However, it can produce some false-negatives, even when patients were symptomatic.

The authors propose that patients with concerning chest x-rays, symptoms such as unexplained chest pain or tiredness, or evidence of heart muscle damage or dysfunction should ideally have a cine CT scan that can image the heart moving in relation to the epicardial wires. Although this can also result in a false-positive, CT is less risky for pediatric patients because radiation doses are now much lower for this non-invasive imaging method.

If cine CT is not available, they advocate that patients undergo catheter angiography to confirm the diagnosis before taking a patient to surgery.

“The use of pacemakers and defibrillators in children is growing,” noted Dr. Mah. “As more epicardial devices are implanted, more children may be at risk for developing coronary compression from their leads. We hope to increase awareness among healthcare providers and patients of this important, possibly preventable, and potentially fatal complication and provide a useful screening algorithm to detect at-risk patients and ultimately prevent complications.”

“This article clearly emphasizes the need to not only carefully evaluate the potential site of electrode head fixation to avoid coronary injury, but also the need to evaluate closely where to route the electrode body to the device pocket,” commented Gerald A. Serwer, MD, FHRS, pediatric cardiologist at the University of Michigan’s C.S. Mott Children’s Hospital, Michigan Medicine, Ann Arbor, MI, USA, in an accompanying editorial.

Dr. Serwer emphasizes that all cardiologists who have patients with epicardial electrodes should always be aware of this potential complication and periodically assess patients for coronary issues with at least a periodic chest x-ray. When evidence strongly suggests ischemia secondary to coronary compression due to electrode position, electrode replacement must be considered in view of the potential morbidity and mortality. “I strongly concur with the authors that any additional information one can obtain to aid in risk assessment would be of benefit and



Raymond Schaerf, MD, is a cardiothoracic surgeon who specializes in performing delicate procedures to remove wires from old or malfunctioning defibrillators and pacemakers. Credit: Cedars-Sinai.

agree with them that additional studies to establish the efficacy of nuclear cardiology techniques are indicated,” concluded Dr. Serwer.

New Cardiothoracic Surgeon Speaks With Heart

Raymond Schaerf, MD, a cardiothoracic surgeon, likes to joke that most people pack their cellphones with photos of their smiling children. His cellphone, however, is stocked with pictures of the human heart.

The photos are not Valentines and display the vital human organ in various states of distress and complication—those that can occasionally arise from implanted cardiac devices such as pacemakers and defibrillators. Schaerf specializes in lead extractions, a delicate procedure performed to remove wires that are old, malfunctioning, infected or causing a patient difficulty.

Schaerf, who joined the Smidt Heart Institute less than a year ago, recently sat down with *The Bridge* to talk about his work and his life outside of it. Below is an edited version of the conversation.

What is your main role at Cedars-Sinai?
I take care of infected or malfunctioning pacemakers and defibrillators. My task is to remove the infection or a malfunctioning part and put in a new system for the patient.

It sounds very challenging.
Sometimes, with these devices, things can go wrong immediately. Other times, they’ve been in there for years and years, which makes it a lot harder to get

them out. That's why I get called in—to decide if extraction is necessary and to assess the risk.

It's a complicated procedure with a lot of risks, but I'm in a place where some of the most incredible surgeries are performed by my colleagues. The care for patients here is outstanding.

How many procedures like that have you performed?

I average about 100 a year. I've done over 4,000 in my career.

How long do the surgeries take?

Usually from one to four hours.

How soon can a patient return to normal activities?

If it's not an infection, sometimes people can go home and go back to work the next day. But some of my patients are in their 90s, and they have to take it easy. Infected patients need to stay at least three or four days to determine what organism caused the infection.

Still, it's not uncommon to have someone fly in here for the surgery and then leave the next day. They could go back to work soon after that, but we usually restrict their activities for a while.

Why did you choose to become a surgeon?

I was going to be a nephrologist. My mentor was my father's doctor. My father had kidney problems. I was really excited about it. And one day as a medical student, his partner asked me if I would like to do a peritoneal dialysis catheter implant. And I said sure. I'll never forget this. The patient was a 35-year-old woman. She looked terrible because of renal failure and, mind you, this is 1970—and I'm trying to push this device in there and finally it pops in and I placed the catheter in there. My mentor's partner asks me, "You want to put a purse string suture on that?" I said, "A who?" I had no idea. So, he showed me.

The patient got much better. I remember my feet didn't touch the ground for about an hour afterward. I was walking on air. I thought surgery was very cool. I was hooked.

Do you have any hobbies?

Not anymore. But I do get addicted to some TV shows. Breaking Bad, The Good Wife, shows like that.


You speak five languages—English, German, Spanish, French and Yiddish.

I was born in Romania but came to America when I was a baby. I was an only child, too. My parents would have dinners and all these eastern European refugees would be talking in different languages around the table. I wanted to learn the languages because I was curious what they were saying.

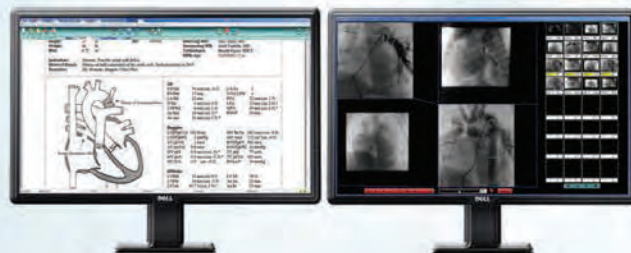
How did you get to Cedars-Sinai?

There's no such thing as asking why someone wants to come to Cedars-Sinai, but I had some relationships with doctors for years. I'd met them at meetings and given a few talks and done some investigations with them. Also, I did extractions for them years ago.

And when a need came up here, they asked if I would consider coming here. I said, "Of course." It's a great place to be.



DIGISONICS
Mastering the art of interpretation



Congenital Reporting & Imaging Solutions for Cath, Echo and MR

Trend plots with pediatric and fetal z-scores

Quick report capability for bringing forward data from previous reports

Extensive library of modifiable Mullins diagrams with 300 exclusive to Digisonics

Robust data mining and business analytics package

www.digisonics.com
Visit us at PICS-AICS 2019!



Boston Children's Health Physicians
Until every child is well™

Chief of Pediatric Cardiology

The Department of Pediatrics at New York Medical College and Maria Fareri Children's Hospital/Westchester Medical Center along with Boston Children's Health Physicians, LLP (BCHP) seek a Chief, Section of Pediatric Cardiology. The Section includes 15 attending pediatric cardiologists, employed by BCHP, who manage inpatient Pediatric Cardiology activities at Maria Fareri Children's Hospital and affiliated institutions of the WMC Health System, which is comprised of 10 hospitals in the 6000sq mile area of the lower Hudson Valley of NY State. The service is closely aligned with the system's Pediatric Cardiothoracic Surgery program run by Khanh Nguyen, MD, Chief. Clinical services include the entire spectrum of outpatient clinical and diagnostic activities in a variety of ambulatory settings across the region. The Section has both NIH and other sponsored research projects and participates in several clinical trials. Candidates should have achieved the academic rank of at least Associate Professor and have demonstrated organizational and leadership skills.

Boston Children's Health Physicians is committed to excellence through diversity and inclusion and welcomes candidates of all backgrounds.

Interested candidates should send CV and cover letter to:

Leonard J. Newman, MD

Chairman Dept. of Pediatrics
New York Medical College
40 Sunshine Cottage Road
Skyline Suite #1N-C08
Valhalla, NY 10595

Leonard_Newman@NYMC.edu



Pediatric Cardiologist

The Greater Louisville, Central and Western Kentucky Cardiology Clinic is looking for a pediatric cardiologist to join a team of three cardiologists. "Title: Assistant Professor of Clinical Pediatrics, Outpatient Community Congenital Cardiology."

The Heart Institute at Cincinnati Children's has expanded their outreach program to include outpatient Cardiology Clinics in Greater Louisville, Central and Western Kentucky and have an excellent full-time employment opportunity for a BC/BE fellowship trained pediatric cardiologist to provide outpatient services in their Western Kentucky clinics.

The Greater Louisville, Central and Western Kentucky Cardiology Clinic is a well-respected Cardiology practice, proudly serving the local community, surrounding towns and rural areas including a large Spanish-speaking population.

Depending on individual interests, the successful candidate will also have the opportunity to work closely with The Heart Institute team at Cincinnati Children's. The Heart Institute provides complex cardiac care to the entire spectrum of congenital and acquired heart disease with excellent subspecialty expertise in electrophysiology, heart failure and transplant, advanced imaging, cardiac intensive care and adult congenital heart disease. This growing and dynamic program performed over 700 cardiac surgeries in 2017-18, helping children from all over the United States and Internationally.

Qualifications

- MD degree or equivalent
- Trained in an accredited Pediatric or Med Peds Residency program or equivalent
- Completed a General Pediatric Cardiology Fellowship and may have completed an additional year of relevant subspecialty training (e.g. advanced imaging, fetal cardiology), is preferred but not mandatory
- Board eligible or board certification in pediatric cardiology by the American Board of Pediatrics
- Demonstrate outstanding interpersonal skills
- Must be eligible for an unrestricted medical license in the states of Ohio and Kentucky

Desirable

- Bilingual Spanish speaking candidates
- Interest in teaching

Academic title will commensurate with academic credentials. Compensation is based on training and experience. Generous Benefit Package includes: Salary, Group Health, and Dental, Vision, Short Term and Long Term Disability and Life Insurance effective 1st day of employment. Cincinnati Children's funds a defined contribution retirement plan for employees. Relocation Benefits. 403b retirement savings, Tuition Assistance CME, and paid time off. Consideration may be given to applicants seeking visa support.

We invite you to send a letter of interest and curriculum vitae to:

Andrew Redington, MD, c/o Deborah Mancini

HR consultant, Physician and Faculty Recruitment

Deborah.Mancini@cchmc.org

Cincinnati Children's is an Equal Opportunity Employer. Qualified applicants will receive consideration for employment without regard to race, color, religion, sex, national origin, age, physical or mental disability, military or veteran status, sexual orientation, or other protected status in accordance with applicable federal, state, and local laws and regulations. Cincinnati Children's is committed to building a diverse faculty and strongly encourages women, minorities, individuals with disabilities and veterans to apply.



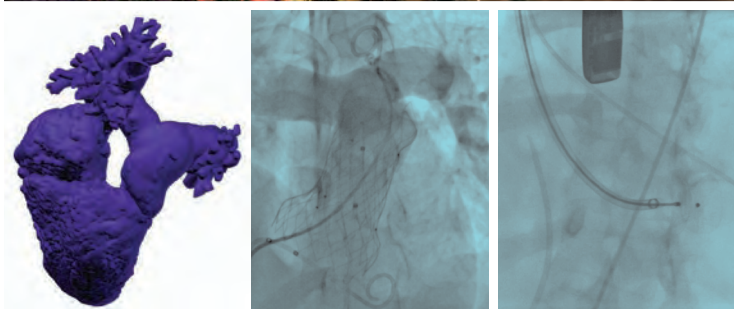
PICS-AICS

Pediatric and Adult Interventional Cardiac Symposium

SAVE THE DATE SAN DIEGO

MARRIOTT MARQUIS - SAN DIEGO MARINA
SEPTEMBER 4-7, 2019

Focusing on the latest interventional catheter
strategies for congenital and structural heart
disease in children and adults.



LIVE CASE DEMONSTRATIONS | ABSTRACT SESSIONS
TAPED CASES | HOT DEBATES | BREAKOUT SESSIONS
MY NIGHTMARE CASE IN THE CATH LAB

WWW.PICSYMPOSIUM.COM



Congenital Cardiac Intensivist

The Heart Center (THC) at Nationwide Children's Hospital, the primary pediatric teaching facility for The Ohio State University in Columbus Ohio, is recruiting an attending physician, at any academic level, for the Cardiothoracic Intensive Care Unit (CTICU) to join a group of eight multi-background academic cardiac intensivists and ten dedicated nurse practitioners devoted to the CTICU providing 24/7 in house coverage. Our free-standing CTICU is a 20 bed unit with 600 admissions per year (medical and surgical); an average daily census of 12. Candidates must have completed fellowship training in pediatric cardiology and/or critical care that included advanced cardiac intensive care training. Preference will be given to those who are boarded in pediatric cardiology and interested in an academic center with research and leadership opportunities for the candidate's professional growth. THC's comprehensive services include hybrid palliation, comprehensive single ventricle program, thoracic organ transplantation, blood conservation strategies, and cardiac mechanical support. Current annual clinical metrics for THC includes: over 500 cardiothoracic surgeries, over 700 cardiac catheterizations and EP procedures, and over 13,000 cardiology outpatient visits. We have a pediatric and pediatric/adult combined cardiology fellowship programs. We participate in numerous multicenter clinical trials and quality initiatives including the JCCHD QI Collaborative. We are directly linked to our Center for Cardiovascular and Pulmonary Research which has an NIH T-32 training grant. Interested candidates are encouraged to submit their curriculum vitae to Janet Simsic, MD, Director of the Cardiothoracic Intensive Care Unit, Nationwide Children's Hospital, T2279, 700 Children's Drive, Columbus, OH 43205

janet.simsic@nationwidechildrens.org

The Ohio State University is an Equal Opportunity, Affirmative Action Employer. Women, minorities, veterans, and individuals with disabilities are encouraged to apply.



THE OHIO STATE UNIVERSITY
COLLEGE OF MEDICINE



Do your
life's best work
at Auckland DHB



Paediatric Cardiologist opportunities available with Starship Child Health, New Zealand

Starship Child Health is the leading provider of paediatric care in New Zealand and the South Pacific, providing world-class inpatient, outpatient, trauma, emergency, and urgent care to children and their whānau. Starship is part of the Auckland District Health Board, New Zealand's largest tertiary healthcare provider.

The Greenlane Paediatric and Congenital Cardiac Service (PCCS) is a national service based at Starship Children's Health, Auckland. It is the sole provider of cardiology and cardiac surgical services for infants and children with congenital and acquired heart disease for New Zealand and a number of Pacific Island nations. It also provides a foetal and adult congenital cardiology service.

The unit has a catchment population of four and a half million and we provide a full range of surgical and cardiological investigations and procedures with over 400 cases per year of which 320 are bypasses. You would be working in a department with 9 other cardiologists and 3 cardiac surgeons, 4 fellows in training and a well-established multi-disciplinary team and will participate in all aspects of the clinical service.

We have two positions available:

Interventional Cardiologist (Permanent) (AUC04138) - for a paediatric cardiologist with a strong subspecialty experience/expertise in interventional cardiology.

Click here to view the position: <https://tas-adhbrac.taleo.net/careersection/10520/jobdetail.ftl?lang=en&job=AUC04138>

Electrophysiologist (Fixed Term) (AUC03683) - Have a subspecialty interest in Arrhythmia Management and Electrophysiology. This would be an advantage but is not essential.

Click here to view the position: <https://tas-adhbrac.taleo.net/careersection/10520/jobdetail.ftl?lang=en&job=AUC03683>

As the ideal candidate for either role you will:

- Possess and demonstrates excellent interpersonal skills and enjoy working in a collegial environment
- Demonstrate interest and potential to actively participate in departmental activities including teaching, audit and research
- be eligible for vocational registration with Medical Council of New Zealand. If you are not currently registered in New Zealand and have overseas medical qualifications, you will be required to provide source verification of your qualifications for your registration application. For more information about the registration process and source verification of qualifications, please visit www.mcnz.org.nz.

New Zealand is a land of outstanding natural beauty and breath taking scenery, with huge opportunity for all outdoor pursuits so is a great place to live, work and have a great work life balance. Auckland is the largest city in NZ and offers a great outdoors experience with beaches, mountains, concerts, sports, shopping, wining and dining. More information about living and working in New Zealand is available on www.newzealandnow.govt.nz

To apply, please click on the job title above and to submit your application attaching your latest CV and cover letter. You can also find these ads on our website www.careers.adhb.govt.nz quoting the ref #s above. For more information about the role or for help with applying, please contact Sonu Anand on sonua@adhb.govt.nz. We can also support you with your registration, immigration and relocation requirements.

For the largest health sector job board in New Zealand, visit www.kiwihealthjobs.co.nz



Subscribe Electronically to CCT

Free on the Home Page

www.CongenitalCardiologyToday.com



Recruit with CCT

Recruitment advertisements are listed

- In print and electronic monthly issue
- On our website
- In our monthly email blast

Contact: Kate@cct.bz



CONGENITAL CARDIOLOGY TODAY

Founder & Senior Editor

Tony Carlson
Tony@cct.bz

Publisher & Editor-in-Chief

Richard Koulbanis

Co-Founder & Medical Editor

John W. Moore, MD, MPH
Dr.John@cct.bz

Senior Editor of Special Projects

Kate Baldwin
Kate@cct.bz

Article Editor

Caryl Cornell

Staff Editor

Virginia Dematatis
Loraine Watts

Editorial Board

Teiji Akagi, MD
Zohair Al Halees, MD
Mazeni Alwi, MD
Felix Berger, MD
Fadi Bitar, MD
Jacek Bialkowski, MD
Mario Carminati, MD
Anthony C. Chang, MD, MBA
John P. Cheatham, MD
Bharat Dalvi, MD, MBBS, DM
Horacio Faella, MD
Yun-Ching Fu, MD
Felipe Heusser, MD
Ziyad M. Hijazi, MD, MPH
Ralf Holzer, MD
Marshall Jacobs, MD
R. Krishna Kumar, MD, DM, MBBS
John Lamberti, MD

Gerald Ross Marx, MD
Tarek S. Momenah, MBBS, DCH
Toshio Nakanishi, MD, PhD
Carlos A. C. Pedra, MD
Daniel Penny, MD, PhD
James C. Perry, MD
Shakeel A. Qureshi, MD
P. Syamasundar Rao, MD
Andrew Redington, MD
Carlos E. Ruiz, MD, PhD
Girish S. Shirali, MD
Horst Sievert, MD
Hideshi Tomita, MD
Gil Wernovsky, MD
Zhuoming Xu, MD, PhD
William C. L. Yip, MD
Carlos Zabal, MD

© 2019 by Congenital Cardiology Today
(ISSN 1554-7787-print; ISSN 1554-0499-online)
Published monthly. All rights reserved.

Statements or opinions expressed in Congenital Cardiology Today reflect the views of the authors and sponsors, and are not necessarily the views of Congenital Cardiology Today.

Official Publication of the CHiP Network

CHiP NETWORK
CONGENITAL HEART INTERNATIONAL PROFESSIONALS

The congenital heart professionals network exists to facilitate communications between congenital heart professionals locally, regionally, and globally.

JOIN TODAY

www.chip-network.org



Funded by Cincinnati Children's Heart Institute



Repositionable and Retrievable
Prior to Release

Tight and Compact Windings
Ensure Efficient Occlusion

Designed to Match Individual
Morphologies and Sizes

NIT-OCCLUD[®] Coil System

for PDA Closure

Designed For the Safe and Atraumatic Occlusion of the
Congenital Heart Defect PDA (Patent Ductus Arteriosus)

INDICATIONS FOR USE:

The Nit-Occlud[®] PDA coil is a permanently implanted prosthesis indicated for percutaneous, transcatheter closure of small to moderate size patent ductus arteriosus with a minimum angiographic diameter less than 4mm.

NIT-OCCLUD BRIEF STATEMENT:

Do not implant the Nit-Occlud PDA into patients who have endocarditis, endarteritis, active infection, pulmonary hypertension (calculated PVR greater than 5 Wood Units), thrombus in a blood vessel through which access to the PDA must be obtained, thrombus in the vicinity of the implantation site at the time of the implantation or patients with a body weight < 11 lbs. (5kg). An angiogram must be performed prior to implantation for measuring length and diameter of the PDA. Only the pfm medical implantation delivery catheter should be used to implant the device. Administration of 50 units of heparin per kg bodyweight should be injected after femoral sheaths are placed. Antibiotics should be given before (1 dose) and after implantation (2 doses) to prevent infection during the implant procedure. Do not implant the Nit-Occlud PDA in an MR environment. Do not pull the Nit-Occlud coil through heart valves or ventricular chambers. Contrast media should not be injected through the implantation catheter. The catheter must not be connected to high pressure injectors. Patients may have an allergic response to this device due to small amounts of nickel that has been shown to be released from the device in very small amounts. If the patient experiences allergic symptoms, such as difficulty in breathing or swelling of the face or throat, he/she should be instructed to seek medical assistance immediately. Antibiotic prophylaxis should be performed to prevent infective endocarditis during first 6 months after coil implantation. Potential Adverse Events: Air embolism, Allergic reaction to drug/contrast, Apnea, Arrhythmia requiring medical treatment or pacing, Arteriovenous fistula, Bacterial endocarditis, Blood loss requiring transfusion, Chest pain, Damage to the tricuspid or pulmonary valves, Death, Embolization of the occluder, requiring percutaneous or surgical intervention, Endarteritis, False aneurysm of the femoral artery, Fever, Headache/ Migraine, Heart failure, Hemolysis after implantation of the occluder, Hypertension, Hypotension or shock, Infection, Myocardial infarction, Occluder fracture or damage, Perforation of the heart or blood vessels, Stenosis of the left pulmonary artery or descending thoracic aorta, Stroke/TIA, Thromboembolism (cerebral or pulmonary), Valvular Regurgitation, Vessel damage at the site of groin puncture (loss of pulse, hematoma etc.).

Nit-Occlud is a registered trademark of pfm medical Inc.

Rx only CV9064 - 5/17 ©2017 B. Braun Interventional Systems Inc.

Distributed by:

B. Braun Interventional Systems Inc.

824 Twelfth Avenue | Bethlehem, PA 18018 | USA

Tel 877 836 2228 | Fax 610 849 1334 | www.bisusa.org

